



## **Right Side Diaphragmatic Hernia. – A Case Report**

**Asma El-Karouachi<sup>1,2</sup>, Ahmed Elmi Abdirahim<sup>1,2\*</sup>, Zouhair Abdeladim<sup>1,2</sup>,  
Driss Erguibi<sup>1,2</sup>, Hajri Amal<sup>1,2</sup>, Boufettal Rachid<sup>1,2</sup>, Saad Rifki El-Jai<sup>1,2</sup>  
and Chehab Farid<sup>1,2</sup>**

<sup>1</sup>*Service of Digestive Cancer Surgery and Liver Transplantation "Aile 3", Department of General Surgery, University Hospital Centre IBN Rochd of Hassan II University, Casablanca, Morocco.*

<sup>2</sup>*Faculty of Medicine and pharmacy, Hassan II University, Casablanca, Morocco.*

### **Authors' contributions**

*This work was carried out in collaboration among all authors. All authors read and approved the final manuscript.*

### **Article Information**

#### Editor(s):

(1) Dr. Pandiaraja.J, Shree Devi Hospital, India.

(2) Dr. Ashish Anand, GV Montgomery Veteran Affairs Medical Center, USA.

#### Reviewers:

(1) Kirti Savyasacchi Goyal, Maharishi Markandeshwar (Deemed to be University), India.

(2) Krishna Kumar G, India.

Complete Peer review History: <https://www.sdiarticle4.com/review-history/72907>

**Case Study**

**Received 15 June 2021  
Accepted 21 August 2021  
Published 28 August 2021**

## **ABSTRACT**

Congenital diaphragmatic hernia (CDH) is a condition characterized by a defect in the diaphragm leading to protrusion of abdominal contents into the thoracic cavity. Right side diaphragmatic hernia is a rare entity. The surgical incidence remains controversial, particularly for the choice of the surgical approach and technique. The mortality is mainly related to associated injuries.

We report a case of right side diaphragmatic hernia in an 84-year-old man who presented with respiratory distress.

This case highlights rarity of the case and the diagnostic difficulties.

*Keywords: Hernia; diaphragm; treatment; surgery.*

### **1. INTRODUCTION**

The diaphragm is a dome-shaped and thin musculoaponeurotic barrier that plays an

important role in respiratory function [1]. Diaphragmatic injuries include wounds and diaphragm ruptures, due to a thoracoabdominal blunt or penetrating traumas. The incidence

\*Corresponding author: E-mail: [abdirahimahmedelmi7@gmail.com](mailto:abdirahimahmedelmi7@gmail.com), [abdirahim.ahmed@cnsd.dj](mailto:abdirahim.ahmed@cnsd.dj);

ranges between 0.8 and 15 % [2]. Right-sided diaphragmatic hernia is less common than the left-side, as a result of the anatomical position of the liver. The diagnosis of a right side diaphragmatic injury is a challenge for the surgeon because clinical signs are often nonspecific [1]. Diagnosis depends the clinical signs and the imaging [3]. The surgical management remains controversial, particularly for the choice of the surgical approach and technique [2].

## 2. OBSERVATION

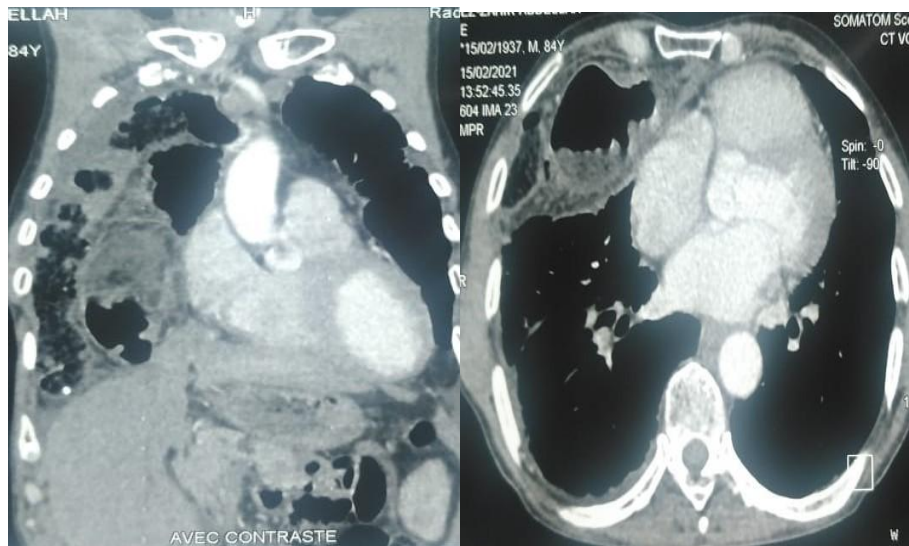
A 84 years-old male was admitted to the general surgery department of the Ibnou Rochd University Hospital in Casablanca with respiratory distress and pain in the right hypochondrium that had been evolving for one month without any other associated clinical signs. His past history included an operation 10 years ago for a pleuropericardial effusion of tuberculosis origin in the department of internal medicine. The clinical examination revealed a sternotomy scar and a soft abdomen. The abdominal CT (Fig. 1) scan showed an appearance suggestive of a large right side diaphragmatic hernia with right stomach and colon in the right hemithorax with right pleural effusion. After a median supra-umbilical incision, a defect was noticed (Fig. 2) in the right dome of diaphragm measuring 10 cm, with whitish granulations on the liver, transverse colon, transverse mesocolon and mesentery. The

underwent suturing of a 10 cm diaphragm perforation with X-stiches, biopsy of the granulations (at the hepatic level of segment VI and epiploic), right thoracic drainage with a Joly drain, inter-hapato-diaphragmatic drainage with a salem probe. Histopathological examination showed granulomatous lesions suggestive of tuberculosis. Postoperative recoveries were uneventful and the patient was followed for 12 months without symptoms.

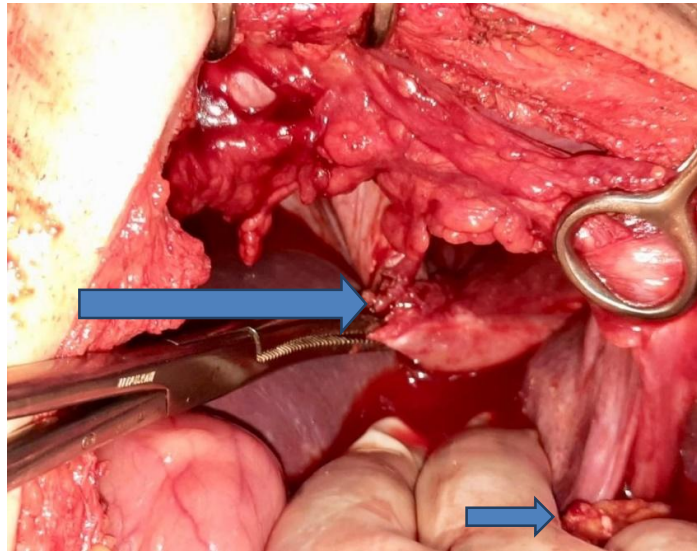
## 3. DISCUSSION

The diaphragm is a large, dome-shaped structure composed of both muscle and tendon. It separates the pleural and peritoneal cavities [4]. In the embryonic development period, fusion defects of the diaphragm can occur, resulting in postero-lateral defects (Bochdalek hernia,95%), anterior-retrosternal defects (Morgagni,4%) and hiatal hernias and septum transversum defects (1%) [4].

Despite the high-speed, mechanized age in which we are living, traumatic right sided diaphragmatic hernias are extremely rare. The rarity with which we see traumatic right-sided diaphragmatic hernias may be explained by the fact that the liver shields the dome of the right diaphragm. It may also be that an injury of sufficient severity to produce such a hernia may often result in the death of such patients before surgical repair can be instituted [5].



**Fig. 1 . CT scan shows a large right side diaphragmatic hernia with right stomach and colon in right hemithorax**



**Fig. 2. This image shows a diaphragmatic hernia in the right dome**

The diagnosis of congenital diaphragmatic hernias in adults is uncommon with 0.17% incidence [6].

The incidence of diaphragmatic injury is often underestimated in over half the cases, especially those located on the right side [2].

The diaphragmatic hernia in our case is of an unknown etiology. The patient was not previously known to have diaphragmatic hernia.

Nayak et al. described severe symptoms, in 46% of Congenital diaphragmatic hernia cases with 32% of mortality due to visceral strangulation [3]. Moreover, the literature analysis shows a variable presentation with delayed symptoms (5–45.5%) [3].

The clinical presentation of adult patients with right side diaphragmatic hernia may vary from an incidental finding on imaging to strangulation of contents with significant morbidity and mortality [4].

Right side diaphragmatic hernia is usually associated with only respiratory issues because partial liver displacement blocks further herniation of hollow viscera [3].

Chest X-ray and barium studies are useful for determining which viscera have herniated into the thorax [3].

Computed tomography can be considered the ideal non-invasive technique for diagnosis,

offering the unique opportunity to evaluate the presence of diaphragmatic defect, size, exact location and contents of the various types of diaphragmatic hernia. Once diagnosed, surgical intervention is necessary to prevent complications [7].

The differential diagnosis of right side diaphragmatic hernia should always include Hepatopulmonary fusion, lung malformations, sequestrations, cysts, tumors, sarcoidosis, etc... a diagnosis of which would significantly alter the surgical intervention, management, and outcomes [8].

Recurrent diaphragmatic hernia is a dominant surgical challenge [9].

The treatment of right side diaphragmatic hernia is surgical and encompasses both reduction of the hernia contents and closure of the diaphragmatic defect [4]. Surgical treatment may be realized either through laparotomy or thoracotomy or video-assisted approach [1], with simple tension free suturing of the defect with non-absorbable sutures (herniorrhaphy) or mesh repair (hernioplasty). The open thoracic and abdominal approaches can be combined in difficult cases [4].

Right-sided hernias seem to have a worse prognosis than left-sided ones and may require more support [10].

Mortality and morbidity in right side diaphragmatic rupture are often due to associated intra-abdominal or intrathoracic injuries. Mortality is almost nil in isolated diaphragmatic rupture [1].

#### 4. CONCLUSION

Right side diaphragmatic rupture is rare and is characterised by a diaphragmatic defect of either congenital or traumatic origin with an ascent of the digestive organs into the thoracic cavity. The diagnosis is difficult and often delayed. The management is surgical. surgery is the treatment of choice, above all in emergency setting. Prognosis depends on associated injuries.

#### PATIENT CONSENT

Written informed consent for publication of the clinical details and images was obtained from the patient.

#### ETHICAL APPROVAL

As per international standard or university standard written ethical approval was obtained by the author.

#### COMPETING INTERESTS

Authors have declared that no competing interests exist.

#### REFECENCES

1. Amadou Magagi I, Habou O, Adamou H, Adakal O, Ali Ada MO, Moustapha H, et al. Isolated Right-Sided Posttraumatic Diaphragmatic Hernia. Case Reports in Surgery. 2018;2018:1-3.
2. Thiam O, Konate I, Gueye ML, Toure AO, Seck M, Cisse M, et al. Traumatic diaphragmatic injuries: epidemiological, diagnostic and therapeutic aspects. Springer Plus. 2016;5(1):1614.
3. Testini M, Girardi A, Isernia RM, De Palma A, Catalano G, Pezzolla A, et al. Emergency surgery due to diaphragmatic hernia: case series and review. World J Emerg Surg. 2017;12(1):23.
4. Ayane GN, Walsh M, Shifa J, Khutsafalo K. Right congenital diaphragmatic hernia associated with abnormality of the liver in adult. Pan Afr Med J [Internet]. 2017. [cit e 31 juill 2021];28. Available: <http://www.panafrican-med-journal.com/content/article/28/70/full/>
5. J. Walter Neal, Raleigh NC. Traumatic right diaphragmatic hernia with evisceration of stomach, transverse colon and liver into the richt thorax. Annals of Surgery; 1953.
6. Alshehri FA, Alshahrani MA, Neimatallah MA. Neglected right diaphragmatic hernia with transthoracic herniation of gallbladder and malrotated left liver lobe in an adult. Radiology Case Reports. 2020;15(10): 1792-4.
7. De Marco EA, Merli L, Taddei A, Pulitano SM, Manzoni C, Nanni L. Late-presenting right congenital diaphragmatic hernia with severe hypotrophy of the right lobe of the liver. International Journal of Surgery Case Reports. 2015;17:28-30.
8. Patel S, Rael J. Right-Sided Congenital Diaphragmatic Hernia Caused by Hepatopulmonary Fusion. Lee ACW,  diteur. Case Reports in Pediatrics. 2020; 2020:1-6.
9. Alghamdi A, Raboe E. Right Bochdalek congenital diaphragmatic hernia: A tertiary center's experience over 13 years. Ann Pediatr Surg. 2021;17(1):24.
10. Tovar JA. Congenital Diaphragmatic Hernia. Orphanet J Rare Dis. 2012;7(1):1.

  2021 El-Karouachi et al.; This is an Open Access article distributed under the terms of the Creative Commons Attribution License (<http://creativecommons.org/licenses/by/4.0>), which permits unrestricted use, distribution, and reproduction in any medium, provided the original work is properly cited.

*Peer-review history:*  
The peer review history for this paper can be accessed here:  
<https://www.sdiarticle4.com/review-history/72907>