



# **Familial Adenomatous Polyposis Coli in East Africa: A Case Report and Review of the Literature**

**Richard Wismayer<sup>1,2\*</sup>**

<sup>1</sup>*Department of Surgery, Masaka Regional Referral Hospital, Masaka, Uganda.*

<sup>2</sup>*Department of Pathology, School of Biomedical Sciences, College of Health Sciences, Makerere University, Kampala, Uganda.*

## **Author's contribution**

*The sole author designed, analyzed and interpreted and prepared the manuscript.*

## **Article Information**

DOI: 10.9734/JAMMR/2020/v32i1730647

*Editor(s):*

(1) Dr. Ashish Anand, GV Montgomery Veteran Affairs Medical Center, University of Mississippi Medical Center & William Carey School of Osteopathic Medicine, USA.

(2) Dr. Emin Umit Bagriacik, Gazi University, Turkey.

*Reviewers:*

(1) P. V. Kamala Kumari, Vignan Institute of Pharmaceutical Technology, India.

(2) D. Clement Wilfred, MS Ramaiah Medical College, India.

Complete Peer review History: <http://www.sdiarticle4.com/review-history/61642>

**Case Study**

**Received 20 July 2020**

**Accepted 26 September 2020**

**Published 02 October 2020**

## **ABSTRACT**

**Introduction:** Familial adenomatous polyposis (FAP) is a rare diagnosis in East Africa. The author reports a case of a 21 year old gentleman presenting with occasional passage of blood stained stool, and found to have familial adenomatous polyposis coli. This is followed by a literature review on the pathogenesis, clinical features and treatment options of FAP in East Africa.

**Presentation of Case:** This patient presented with a strong family history of familial adenomatous polyposis, blood stained stool and a rectal mass. A total proctocolectomy and ileoanal anastomosis was carried out. The postoperative course of this patient was uneventful.

**Discussion:** The typical gross pathological and histological features of familial adenomatous polyposis and rectal adenocarcinoma were seen on the resected colorectal specimen. In addition this study reviews the literature regarding the clinical presentation, pathological characteristics and treatment options of familial adenomatous polyposis coli.

**Conclusion:** FAP should always be considered in a young patient presenting with a strong family history of CRC. Colonoscopy should be performed on these patients with early symptoms and those patients with a strong family history of FAP. In East Africa, the creation of a permanent stoma is unacceptable and therefore a proctocolectomy and Brooke ileostomy will not be a desirable option in a young patient in this part of the world.

**Keywords:** CRC: Colorectal carcinoma; FAP: Familial adenomatous polyposis; MUTYH: mut Y homolog gene; APC: adenomatous polyposis gene.

## 1. INTRODUCTION

Familial adenomatous polyposis (FAP) is an inherited cancer-predisposition syndrome of the large bowel. The incidence of FAP has been reported to be 1 in 7,000 to 1 in 22,000. It is inherited in an autosomal dominant fashion and chromosome 5q21 is the location of the adenomatous polyposis coli (APC) gene [1]. It is less common in females than in males and occurs around the age of puberty. 20-30% of patients with FAP result from spontaneous germline mutations [2]. By 40 years of age the disease penetrance is nearly 100% [3,4].

Hundreds to thousands of adenomatous polyps early in their teens or twenties develop in the colon and rectum with the risk of developing into colorectal carcinoma being 100%. Adenomatous polyps develop in the late teens to early twenties and in the third decade symptoms may typically develop. Patients are typically asymptomatic before 15 years of age and on colonoscopy no macroscopically visible polyps are seen [5]. Numerous microscopic polyps and small polyps are seen in some cases and these patients are normally asymptomatic [6]. A bloody rectal discharge is the most common symptom. However, other symptoms include tenesmus, diarrhoea, abdominal pain and large bowel obstruction [7]. An ominous finding is the presence of bleeding, diarrhoea and abdominal cramps and in these patient's invasive malignancy needs to be ruled out [2,8]. In the absence of malignant transformation of a colonic polyp the disease may be asymptomatic. Apart from classic FAP there are variant forms such as Gardner's syndrome, Turcot syndrome and attenuated FAP. The average age by which carcinoma develops is 39 years in the classic form of FAP. Whilst the average age for colorectal carcinoma to develop is 55 years in the attenuated form of FAP in which the formation of polyps is delayed. The mortality from FAP tends to occur 20 years earlier than the mortality from sporadic colorectal carcinoma.

CRC is the second most common cancer in women worldwide (614,000 cases; 9.2% of the total) and the third most common cancer in men (746,000 cases; 10% of the total) [9]. In Sub-Saharan Africa a low incidence rate is reported compared to the high incidence rates found in Europe, North America and Australia [10]. In

Uganda, the Kampala Cancer Registry has shown that the incidence of colorectal carcinoma is increasing especially among women [11]. There has been a 4.1% annual percentage change in the incidence of colorectal carcinoma in females in Uganda which is a greater increase than in males [11].

Approximately 30% of CRC are familial and in 5-10% of CRC, mutations in important cancer susceptibility genes are detectable [12]. First degree relatives of patients with newly diagnosed adenomas or invasive CRCs are at increased risk of inherited CRC [12]. FAP is a hereditary colorectal cancer syndrome and malignant change occurs in all affected family members [13]. Twenty years following the diagnosis of FAP all affected family members will develop malignancy. At 21 years of age, 7% of untreated FAP patients may develop colorectal carcinoma and by 45 years of age, 90% of untreated FAP patients may develop colorectal cancer [1].

Colonoscopy is the mainstay of diagnosis and the presence of 100 or more polyps which are proven to be adenomas is confirmatory for diagnosis [5]. Polyps cannot be confirmed to be adenomas on double contrast barium enema [5]. Histologic confirmation of adenomatous polyps with a diffuse distribution throughout the colon and rectum confirms the diagnosis. Upper GI endoscopy is essential to detect any upper GI polyps. All children of affected parents and family members should therefore undergo screening and colonoscopy should be done annually on first degree relatives.

The purpose of this case and review of the literature is to recognize and understand the pathogenesis, clinical features and treatment options of FAP in East Africa.

## 2. CASE REPORT

A 21 year old gentleman was admitted to our Hospital with occasional passage of blood stained stool. His family history reported a father that had a Hartman's procedure for sigmoid colon cancer as he had presented to hospital with large bowel obstruction. His father died at 40 years of age from metastatic colon cancer. His paternal uncle also had carcinoma of the colon and had a pan-proctocolectomy at the age of 30 years. A 33 year old sister was also reported of

having had a colonoscopy which showed multiple polyps involving all the colon.

On examination his abdomen was soft and nontender, without any organomegaly, ascites or masses. Rectal examination revealed a hard rectal mass and multiple small polyps some of which were prolapsing through the anus. Colonoscopy was carried out which showed multiple and diffuse polyps which were later found to be adenomas hence supporting the diagnosis of FAP.

On admission to hospital he has a haemoglobin of 8.3 g/dl. Serum electrolytes and liver function tests were all within normal limits. Three transfusions were given to optimize the patients' haemoglobin prior to surgery. A total proctocolectomy and ileoanal anastomosis with a temporary diverting loop ileostomy was carried out. Pathological examination of the resected specimen revealed complete mucosal involvement with many polyps which ranged in size from 0.5cm sessile polyps to 4.5cm pedunculated polyps. Low grade dysplasia was microscopically found in the polyps. Numerous polyps also similarly carpeted the rectal mucosa. Most of these polyps were pedunculated and ranged in size from 0.5cm to 3cm in diameter. A focus of moderately differentiated rectal adenocarcinoma was seen in the mid-rectum arising from a rectal adenovillous polyp. On pathological staging this revealed a T<sub>2</sub>N<sub>0</sub>M<sub>0</sub> rectal adenocarcinoma. 12 lymph nodes were free from cancer. The patient made an uneventful recovery and was eventually discharged and followed up in the surgical out-patient clinic.

### 3. DISCUSSION

In East Africa, familial adenomatous polyposis is a rare diagnosis. This case illustrates one of the few cases reported in Uganda and in East Africa. In the African setting, FAP presents diagnostic challenges. In many parts of East Africa, colonoscopy services are not readily available. Early detection of asymptomatic cases that have very small polyps can be detected by colonoscopy. Small polyps tend to be very difficult to pick up on double contrast enemas which is an imaging investigation more readily available than colonoscopy. Biopsies cannot also be taken with double contrast barium enemas unlike with colonoscopy.

The father who had a sigmoid colectomy for colon cancer and later died of metastatic cancer

probably had FAP. Whilst the sister had a colonoscopy which showed multiple polyps in keeping with familial adenomatous polyposis. Therefore in East Africa one should consider FAP in a young patient when there is a strong family history of colorectal cancer. In 1971, Menezelio first described multiple polyps of the large bowel [14]. In 1882, Cripps recognized the familial nature of the multiple colonic polyposis [7]. The inherited predisposition that contributes to the formation of adenomatous polyps with the potential to become malignant was elicited by Lockhart-Mummery in 1925 [15]. Gardner et al., described the extracolonic manifestations of FAP in the 1950s. These extracolonic manifestations included osteomas and soft tissue tumors including fibromas, sebaceous cysts and lipomas (Gardner's syndrome). Herrera et al., detected a deletion in the long arm of chromosome 5 as the specific genetic abnormality responsible for multiple colon and rectal polyps in 1986 [16]. Bodmer and Leppert et al., eventually confirmed that the APC gene was located on chromosome 5q [8]. APC gene is a tumor suppressor gene and mutations are in the 5q21 region. This mutation leads to hyperproliferative mucosa and diffuse polyposis throughout the gastrointestinal tract. A sparse polyposis (<1000 polyps) are associated with mutations proximal to codon 1249. A profuse phenotype (<5000 polyps) are associated with mutations between codon 1250 and 1330. A sparse polyposis is seen in mutations distal to codon 1465 [17]. A more aggressive disease course with early GI symptoms is found in mutations at codon 1309 [18].

MUTYH germline mutations cause a clinically heterogeneous spectrum with a wide range of phenotypes. Between ten and a few hundred polyps are found in most biallelic MUTYH mutation carriers. A few patients may develop more than 500 polyps. One third of cases with APC negative classical FAP also have shown biallelic mutations. This is true especially in cases where there is an evident recessive pattern of inheritance. In a study by Graver et al., biallelic MUTYH mutations are found in 2% of patients with 100-999 adenomas, 7% of patients with 20-99 adenomas and 4% of patients with 10-19 adenomas (Grover S et al. [19]).

Molecular techniques may be used for the pre-symptomatic diagnosis of FAP. Mutations in the APC gene may result in truncated APC proteins. This may be caused by point mutations, splicing

mutations or frameshifts (Talseth-Palmer BA et al. [20]). The following events which include splicing mutations, mutations altering transcript stability, imprinting abnormalities and promoter mutations can be detected by the allele-specific-expression assay. The molecular approach used in diagnosing presymptomatic individuals should identify mutations that eventually lead to reduced expression in the gene or shortened proteins (Talseth-Palmer BA et al. [20]). This approach should be particularly useful when analyzing large genes such as the APC gene for which it would be labour intensive to apply the conventional analytical methods.

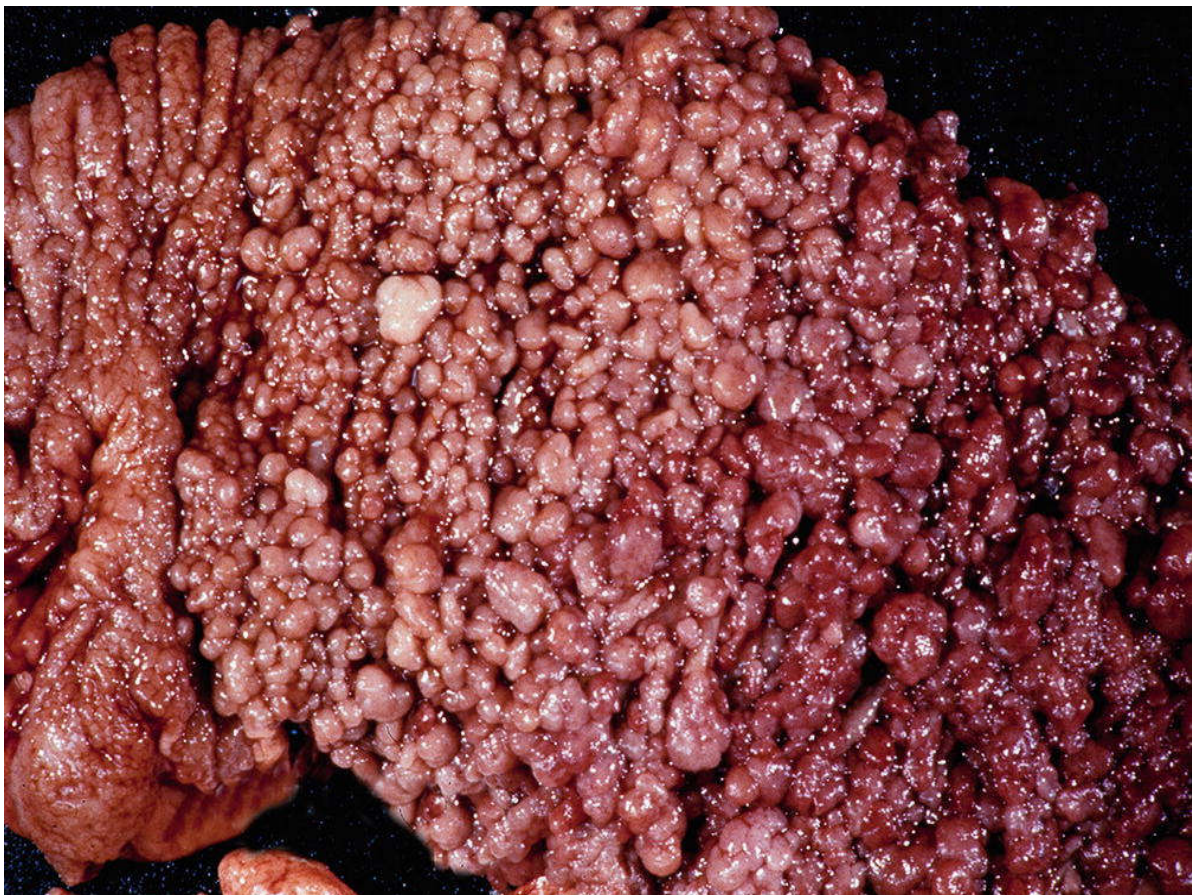
### **3.1 Gross Appearance and Histopathology of Polyps in Familial Adenomatous Polyposis and Colorectal Adenocarcinoma**

The gross pathology of familial adenomatous polyposis shows more than 1000 polyps that can be visualized in the colectomy specimen in Fig. 1. Most polyps tend to be smaller than 1 cm in

size. At the time of colectomy about 25% of FAP patients have carcinoma.

On histology the polyps demonstrate a change in their cell population and are composed of irregularly shaped glands. Some glands demonstrate hyperchromatic larger nuclei and darker cytoplasm. An increase in leukocytes may be visualized in the lamina propria stroma between the glands. The normal cells have small basal nuclei and abundant cytoplasm with large pale goblet vacuoles [21].

The glands which are dysplastic have enlarged pseudostratified hyperchromatic nuclei and darker cytoplasm with smaller to absent goblet vacuoles. Prominent nucleoli and increased mitosis may be seen at higher magnification. These histological changes are typically seen in dysplasia of glandular epithelium. A higher risk of invasive carcinoma is seen in adenomas with more severe dysplastic changes. In adenomas there are more mitosis, abnormal cells and immature cells seen towards the surface [21].



**Fig. 1. Macroscopic appearance of the colon in classic familial adenomatous polyposis. The gross specimen shows dense carpeting with thousands of adenomas of the colonic mucosa**

Invasive adenocarcinoma may display features of desmoplasia, varying degree of gland formation having tall columnar cells. Extensive central necrosis with eosinophilic granular cell detritus may be located in the glandular lumina [21].

### **3.2 Extracolonic Manifestations of Familial Adenomatous Polyposis**

FAP is not considered a colonic disease alone but a generalized disorder of growth regulation. Malignant and benign manifestations include epidermoid cysts, desmoid tumors, osteomas, small bowel tumors, gastroduodenal polyps, hepatobiliary tumors, gastroduodenal polyps, congenital hypertrophy of retinal pigment epithelium and central nervous system tumors.

Upper GI neoplasia and desmoid tumors are the most worrisome of all the extracolonic manifestations of FAP. Periampullary tumors and desmoid tumors have been found to be the major cause of death after prophylactic colectomy in patients with FAP [2,22,23]. Gastric polyps are most hyperplastic polyps situated in the fundus of the stomach and occur in 34% to 100% of FAP patients [3,24]. This is in contrast to duodenal polyps which are adenomas and hence premalignant. These duodenal adenomas should be ablated by excision or electrocoagulation [19]. 10% of patients with FAP tend to develop periampullary carcinoma [23]. FAP patients should be evaluated every 3-5 years with upper GI endoscopy if they are asymptomatic and have a negative upper GI endoscopy. Whilst annual follow up is advocated for patients that have had duodenal adenomas biopsied [25].

Desmoid tumors are benign fibrous lesions and rarely metastatic. These mesenchymal tumors cause death due to local invasion [25]. Mature fibroblasts with occasional mitotic figures and few nuclei are seen on histopathological examination. Desmoid tumors may occur in abdominal incisions, rectus abdominis muscle and small bowel mesentery however the majority occur in small bowel mesentery [25]. Following surgical resection of desmoid tumors in the small bowel mesentery there is a tendency for recurrence. Therefore some authors suggest that surgery for small bowel mesentery tumors should only be reserved for desmoid related complications [22].

### **3.3 Operative Treatment Options for Familial Adenomatous Polyposis**

Patients with FAP should have a prophylactic colectomy to avoid the development of invasive colorectal adenocarcinoma. Avoiding a permanent ileostomy and preserving the anal sphincters is of utmost importance in young patients. Erectile, ejaculatory function as well as urinary bladder function should be preserved in male patients. The operative options of treatment include: (a) subtotal colectomy with ileorectal anastomosis; (b) restorative proctocolectomy with or without an ileal reservoir and ileoanal anastomosis (c) total proctocolectomy and Brooke ileostomy [7].

The most popular treatment for FAP is subtotal colectomy and ileorectal anastomosis. This procedure reduces the risk of damage to the pelvic nerves and avoids a permanent ileostomy. This procedure is popular among young individuals who have an absence of significant rectal polyps are willing to undergo routine surveillance of the residual rectum by proctosigmoidoscopy [23]. The risk of developing rectal remnant cancer after 25 years is between 13% and 59% respectively. The outcome differences may be due to the length of the retained rectal stump, age of the patient, carcinoma in the resected colon and the frequency of proctosigmoidoscopic follow up. [26].

An ideal surgical procedure in FAP patients is restorative proctocolectomy with or without pouch formation and ileoanal anastomosis. The advantages are that it reduces the risk of colorectal malignancy due to complete removal of all the large bowel mucosa. A permanent ileostomy is also avoided and bowel function is preserved. Erectile and ejaculatory function is maintained in young patients by preserving the sacral plexus. In East Africa due to the scarcity of stapling devices and their high cost an ileal pouch ileoanal anastomosis is difficult to perform however in young patients preserving the anal sphincters is of utmost importance [7].

In FAP patients that have developed carcinoma of the lower rectum, proctocolectomy and a Brooke ileostomy is straightforward and has a low complication rate. A permanent ileostomy and excision of the anal sphincters is necessary in this procedure [7]. However, following a restorative proctocolectomy and ileal anastomosis complications which may occur

include anastomotic leak, pelvic sepsis and pouchitis. In order to minimize anastomotic complications temporary diverting loop ileostomy is created which allows for anastomotic healing [27,28].

#### 4. CONCLUSION

FAP should always be considered in a young patient presenting with a strong family history of colorectal cancer. Colonoscopy should be performed in those patients with early symptoms and also those patients with a strong family history of FAP in order to detect early cases before they progress to invasive colorectal adenocarcinoma. In East Africa, the creation of a permanent stoma such as a permanent ileostomy is cosmetically undesirable and socially unacceptable and therefore a proctocolectomy and Brooke ileostomy will not be desirable in a young patient in this part of the world.

#### CONSENT

The author declares that written informed consent was obtained from the patient for publication of this case report.

#### ETHICAL APPROVAL

This case report and review of the literature was partly taken from the PhD proposal of the author which was approved by the Higher Degrees Research and Ethics Committee, School of Biomedical Sciences, College of Health Sciences, Makerere University, Kampala, Uganda and Uganda National Council for Science and Technology (UNCST) and both approvals are preserved by the author.

#### ACKNOWLEDGEMENTS

The author declares that this case report and review of the literature was partly taken from his approved PhD proposal. The author wishes to express his sincere gratitude to Professor Michael Odida and Professor Henry Wabinga for their supervisory contribution to his PhD proposal.

#### COMPETING INTERESTS

Author has declared that no competing interests exist.

#### REFERENCES

1. Beech D, Pontius A, Muni D, Long WP. Familial adenomatous polyposis: A case report and a review of the literature. *J. Natl. Med. Assoc.* 2001;93:208-13.
2. Matsumoto SQ, Lida SQ, Kobori SQ, Mizuno SQ, Nakamura SQ, Hizawa SQ et al. Genetic predisposition to clinical manifestations in familial adenomatous polyposis with special reference to duodenal lesions. *Am J. Gastroenterol.* 2002;97:180-85.
3. Half E, Bercovich D, Rozen P. Familial adenomatous polyposis. *Orphanet J. Rare Dis.* 2009;4:22.
4. Bisgaard ML, Fenger K, Bulow S, et al. Familial adenomatous polyposis (FAP): frequency, penetrance and mutation rate. *Hum. Mut.* 1994;3:121-125.
5. Cruz-Correa M, Giardiello FM. Diagnosis and management of hereditary colonic cancer. *Gastroenterol. Clinical North Am.* 2002;31:537-49.
6. Nawaz Khan Ali, Sumaira MacDonald. Colon polyposis coli syndromes. *E-Medicine*; June 2001.
7. Campbell WJ, Spence RAJ, Park TG. Familial adenomatous polyposis. *Br. J. Surg.* 1994;81:1722-33.
8. Leppert M, Dobbs M, Scambler P et al. The gene for familial adenomatous polyposis maps to the long arm of chromosome 5. *Science.* 1987;235:1411-1413.
9. Ferlay J, Soerjomataram I, Dikshit R, Eser S, Mathers C, Rebelo M et al. Cancer incidence and mortality worldwide: sources, methods and major patterns in GLOBOCAN 2012. *Int. J. Cancer.* 2015; 136(5):E359-86.
10. Vainio H, Miller AB. Primary and secondary prevention in colorectal cancer. *Acta Oncologica.* 2003;42(8):809-815.
11. Wabinga HR, Namboozee S, Amulen PM, Okello C, Mbus L, Parkin DM. Trends in the incidence of cancer in Kampala, Uganda 1991-2010. *Int. J. Cancer.* 2014; 135(2):432-439.
12. Jasperson KW, Tuohy TM, Nekloson DW, Burt RW. Hereditary and familial colon cancer. *Gastroenterology.* 2010;138(6): 2044-58.
13. Segelman J, Granath F, Holm T, Machando M, Mahteme H, Marting A. Incidence, prevalence and risk factors for

- peritoneal carcinomatosis from colorectal cancer. *Colorectal Dis.* 2011;13(6):3.
14. Menezelio D. De excrescentals verrucosa cristois in intestininis crassis dysenteriam passi observatis. *Acta Medicorum Berolinensium.* 1721;4:68-71.
  15. Lockhart-Mummery JP. Cancer and heredity. *Lancet.* 1925;1:427-429.
  16. Herrera I, Kakati S, Gibas, Pietrzak E, Sandberg AA. Gardner syndrome in a man with an interstitial deletion of 5q. *Am J Med Genet.* 1986;25:473-476.
  17. O'Sullivan MJ, McCarthy TV, Doyle CT. Familial adenomatous polyposis: from bedside to benchside. *Am J Clin. Pathol.* 1998;109:521-526.
  18. Caspari R, Friedl W, Mandl M et al. Familial adenomatous polyposis: mutation at codon 1309 and early onset colon cancer. *Lancet.* 1994;343:629-632.
  19. Grover S, Kastrinos F, Steyerberg EW, Cook EF, Dewanwala A, Burbidge LA, Wenstrup RJ, Syngal S. Prevalence and phenotype of APC and MUTYH mutations in patients with multiple colorectal adenomas. *JAMA.* 2012;308(5):485-492.
  20. Talseth-Palmer BA. The genetic basis of colonic adenomatous polyposis syndromes. *Hereditary Cancer in Clinical Practice.* 2017;15:5.
  21. Boman BM, Walters R, Fields JZ, Kovatich AJ, Zhang T, Isenberg GA, Goldstein SD, Palazzo JP. Colonic crypt changes during adenoma development in familial adenomatous polyposis. *Am. J. Pathol.* 2004;165(5):1489-1498.
  22. Anaya DA, Chang GJ, Rodriguez-Bigos MA. Extracolonic manifestations of hereditary colorectal cancer syndromes. *Clin. Colon Rectal Surg.* 2008;21:263-372.
  23. Sagar PM, Pemberton JH. Operations for familial adenomatous polyposis. *Surg. Oncol. Clin. N. Am.* 1996;5:675-688.
  24. Arvantis ML, Jagelman DG, Fazio VW et al., Mortality in patients with familial adenomatous polyposis. *Dis. Colon Rectum.* 1990;33:639-642.
  25. Dozois RR, Berk T, Bulow S et al. Surgical aspects of familial adenomatous polyposis. *Int. J. Colorectal Dis.* 1988;3:1-16.
  26. Aziz O, Athanasiou T, Fazio VW, Nicholls RJ, Darzi AW, Church J. Metanalysis of observational studies of ileorectal versus ileal pouch-anal anastomosis for familial adenomatous polyposis. *Br. J. Surg.* 2006;93(4):407-17.
  27. Kmiot WA, Williams MR, Keighley MR. Pouchitis following colectomy and ileal reservoir construction for familial adenomatous polyposis. *Br. J. Surg.* 1990;77:1283.
  28. Hurlstone DP, Saunders BP, Church JM. Endoscopic surveillance of the ileal pouch following restorative proctocolectomy for familial adenomatous polyposis. *Endoscopy.* 2008;40:437-42.

© 2020 Wismayer; This is an Open Access article distributed under the terms of the Creative Commons Attribution License (<http://creativecommons.org/licenses/by/4.0>), which permits unrestricted use, distribution, and reproduction in any medium, provided the original work is properly cited.

*Peer-review history:*

*The peer review history for this paper can be accessed here:*  
<http://www.sdiarticle4.com/review-history/61642>