



# **Comparing Diagnostic Accuracy of USG and CT Scan in Detecting Fatty Liver in Indonesian Patients: Implications for Screening and Management**

**Anggraheny Soelistyaningtyas <sup>a\*</sup>**

<sup>a</sup> *Universitas Wijaya Kusuma Surabaya, Indonesia.*

**Author's contribution**

*The sole author designed, analyzed, interpreted and prepared the manuscript.*

**Article Information**

DOI: 10.9734/AJMAH/2023/v21i8846

**Open Peer Review History:**

This journal follows the Advanced Open Peer Review policy. Identity of the Reviewers, Editor(s) and additional Reviewers, peer review comments, different versions of the manuscript, comments of the editors, etc are available here: <https://www.sdiarticle5.com/review-history/100360>

**Original Research Article**

**Received: 17/03/2023**

**Accepted: 24/05/2023**

**Published: 03/06/2023**

## **ABSTRACT**

This study aimed to determine the accuracy of non-contrast USG and CT Scan in diagnosing fatty liver in Indonesian patients. Using a diagnostic test design with a cross-sectional approach, patients aged 40 years or older with laboratory examination results supporting NAFLD were selectively chosen from Dr. Soetomo Surabaya Hospital's Radiology Laboratory during February-March 2020. The study found that there is no significant difference in diagnostic accuracy between non-contrast USG and CT Scan in detecting NAFLD. Moreover, the majority of patients with NAFLD were women, and the highest prevalence was observed in the middle age range of 40-49 years. These findings suggest that clinicians should consider these demographic characteristics when screening and managing NAFLD in their patients. The choice of diagnostic test should be based on factors such as availability, cost, and patient preference.

**Keywords:** *Fatty liver; diagnostic test; USG; CT scan; NAFLD.*

\*Corresponding author: E-mail: [uwks.dosen@gmail.com](mailto:uwks.dosen@gmail.com);

## 1. INTRODUCTION

Fatty liver disease is a condition where there is an abnormal accumulation of fat in the liver, causing damage to liver function. This disease is divided into two categories, alcoholic and non-alcoholic fatty liver disease. Alcoholic fatty liver disease is caused by excessive alcohol consumption, while non-alcoholic fatty liver disease (NAFLD) is not related to alcohol consumption [1]. Nonalcoholic steatohepatitis (NASH) is a type of NAFLD that occurs when there is inflammation in the liver. If left untreated, it can progress to cirrhosis, liver failure, or liver cancer. According to recent studies, NAFLD is becoming increasingly prevalent, affecting approximately 25% of the world's population. It is also closely associated with obesity, insulin resistance, and metabolic syndrome [2].

Nonalcoholic steatohepatitis (NASH) is a progressive form of non-alcoholic fatty liver disease (NAFLD) that can lead to serious liver damage. NASH can cause liver fibrosis, cirrhosis, and even liver cancer if left untreated. Risk factors for developing NASH include obesity, insulin resistance, diabetes, and dyslipidemia. Several studies have shown that the prevalence of NASH is increasing worldwide, making it a major public health concern [3].

The diagnosis of NASH requires a liver biopsy, which is an invasive procedure. However, non-invasive methods, such as imaging and blood tests, can be used to screen for NASH in patients with risk factors. Lifestyle changes, such as weight loss, exercise, and a healthy diet, are the first-line treatment for NASH. In addition, medications such as pioglitazone and vitamin E have been shown to be effective in improving liver function in NASH patients [4].

Fatty liver or NAFLD is a common liver disease that can be caused by various factors. Metabolic syndrome, which includes type II diabetes mellitus, overweight, obesity, hyperlipidemia, and hypertension, is the most common factor associated with fatty liver. Other factors include medication use, metabolic abnormalities, nutritional status, starvation diet, or other health problems. Furthermore, more than 50% of patients undergoing bariatric surgery are accompanied by NASH [5].

Ultrasonography is a commonly used imaging modality for detecting fatty liver. The sensitivity and specificity of USG for detecting fatty liver are

approximately 89% and 93%, respectively. However, the sensitivity and specificity decrease with an increase in BMI, and a minimum of 33% fat infiltration is needed to be detected on USG. On USG imaging, fatty liver appears as a homogeneous increase in echogenicity due to fat infiltration compared to the renal cortex, accompanied by a blurry vascular image [6].

Non-contrast CT scan is another imaging modality that can be used to diagnose fatty liver. On CT scan, the fatty liver appears hypodense and darker than the spleen. A diagnosis of fatty liver can be established if the spleen is more than 10 Hounsfield Units brighter than the liver. CT scan is said to be more specific in diagnosing fatty liver than USG, but it is more expensive [7].

The gold standard for diagnosing NAFLD is liver biopsy. Liver biopsy can provide a definitive diagnosis of NAFLD, determine the degree of liver damage, and assess the presence of inflammation and fibrosis. However, liver biopsy is an invasive procedure and carries a risk of complications, and therefore it is not routinely recommended as a diagnostic tool for NAFLD [4].

In Indonesia, there have been no studies conducted at Dr. Soetomo Hospital in Surabaya comparing the appearance of fatty liver on USG with non-contrast CT scan. This current study focused on determining which imaging modality is more accurate in diagnosing fatty liver in Indonesian patients.

## 2. LITERATURE REVIEW

### 2.1 The Anatomy of Hepar

The liver is located in the right hypochondrium area, extending inferiorly to the epigastrium and laterally to the left hypochondrium, and superiorly reaching the apex of the diaphragm. Its posterior boundary is the lumbar vertebrae region to the abdominal wall. The superior, anterior, and posterior surfaces are related to the diaphragm. The inferior or visceral surface is related to the upper abdominal organs such as the gallbladder, pylorus, duodenum, ascending colon, hepatic flexure, right third of the transverse colon, right adrenal gland, and right kidney. The anterior middle part of the inferior surface of the liver is also called the quadrate lobe. The left inferior surface is related to the stomach and the posterior surface is related to the inferior vena cava. The left lateral boundary is the falciform ligament [8].

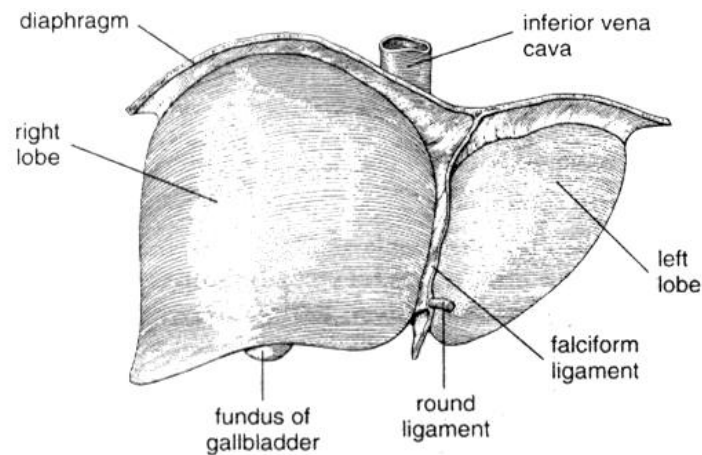
"The liver is divided into three lobes, namely the right lobe, left lobe, and caudate lobe. The right and left lobes are further divided into four segments, with the right lobe consisting of the anterior and posterior segments, and the left lobe consisting of the medial and lateral segments. The caudate lobe is located in the middle of the posterior part of the liver, which separates the right and left lobes [8].

The right lobe of the liver is adjacent to the anterolateral wall of the abdomen, bulging laterally to form a pyramid shape. It is related to the lower lateral surface of the right diaphragm along the mid-axillary line from the 7th to 11th rib [8].

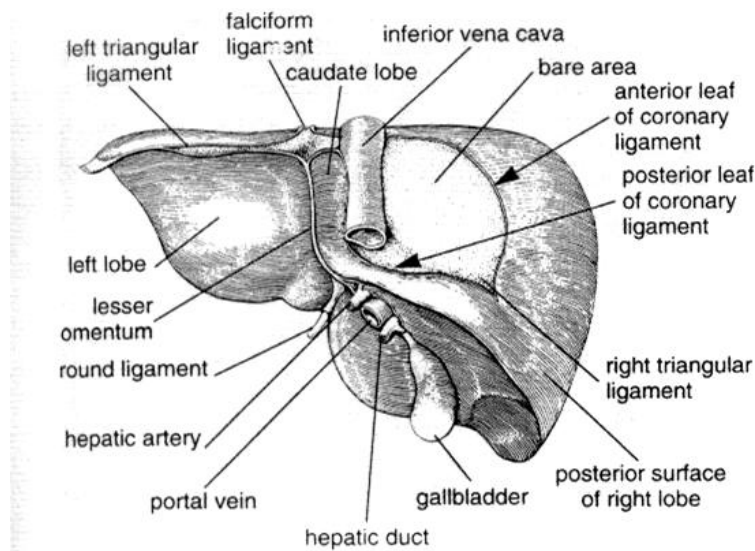
The left lobe of the liver is adjacent to the lower surface of the diaphragm. The caudate lobe is

the smallest lobe and is related to the lumbar region of the posterior abdominal wall and downward to the thoracic wall. The anterior boundary of the caudate lobe is marked by the back surface of the left portal vein, and the posterior boundary is the inferior vena cava [8].

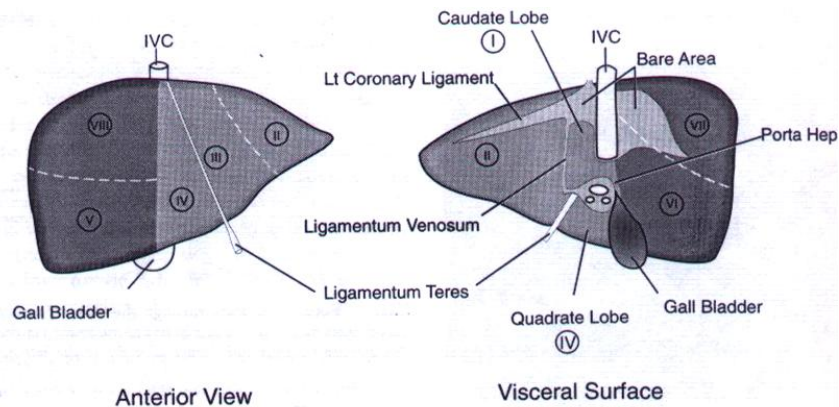
The inferior vena cava passes through the bare area between the anteroinferior and posterosuperior surfaces of the coronary ligament. The right kidney and right adrenal gland are located near the lateral and inferior part of the bare area. The boundaries of the bare area are the falciform ligament, the right anteroinferior and posterosuperior coronary ligaments, the right triangular ligament, the gastrohepatic ligament, the left anterior and posterior coronary ligaments, and the left triangular ligament [8].



**Fig. 1. The anterior surface of the liver [8]**



**Fig. 2. Posterior surface of the liver [8]**



**Fig. 3. Diagram of liver segmental division [9]**

To determine the position of a liver lesion needed for a surgical plan, 8 segments can be utilized. Clockwise, segment I corresponds to the caudate lobe, segments II and III represent the left and right lateral segments of the left lobe, segment IV is associated with the quadrate lobe, segments V and VI correspond to the anterior and posterior segments of the right inferior lobe, and segments VII and VIII are related to the superior part of the right lobe [9].

## 2.2 Pathogenesis of Fatty Liver

The liver is a vital organ responsible for lipid metabolism. Lipids circulate in the bloodstream as lipoproteins, which are composed of hydrophobic lipids surrounded by phospholipids and apoproteins.

The exact mechanism of fatty liver formation remains unclear. It occurs when the rate of lipogenesis exceeds that of lipolysis, resulting in an accumulation of fat in the liver. This happens when the amount of fatty acids delivered to the liver is more than the required quantity for mitochondrial oxidation as energy and for the synthesis of lipids and phospholipids. This mechanism explains the hepatic steatosis observed in obesity. Other possible causes of fatty liver include a reduction in fatty acid utilization in the liver due to mitochondrial oxidative impairment or a decrease in lipoprotein synthesis, which leads to fat accumulation. Insulin resistance is also a significant factor in fatty liver development, as insulin increases triglyceride resistance in hepatocytes. Insulin resistance can increase steatosis because high levels of insulin inhibit the process of fatty acid oxidation in the mitochondria.

One of the main hypotheses suggests that the storage of triglycerides causes stress on the

oxidation and peroxidation of lipids, which is induced by hepatic cytochrome P4502E1 (CYP2E1). This induction produces free radical oxygen products that result in peroxidation of hepatocyte membranes. The damage to hepatocytes leads to cellular inflammation, which marks the beginning of the inflammatory cytokine cascade, ultimately causing tissue damage. The relationship between the degree of inflammation and the development of fibrosis and cirrhosis has been extensively studied [10,11].

Fibrosis in nonalcoholic steatohepatitis (NASH) may be perisinusoidal, centrilobular, or septal. Liver fibrosis or cirrhosis occurs in 15-50% of patients with NASH, and almost 30% of patients with fibrosis develop cirrhosis after 10 years. Histological patterns range from fatty degeneration (steatosis) to lobular inflammation (hepatitis). A diagnosis of NASH can be confirmed through histological evaluation, which may include steatohepatitis, ballooning hepatocytes, and septal fibrosis or degeneration [6,12].

Overweight (BMI > 25 kg/m<sup>2</sup>) and obesity (BMI > 30 kg/m<sup>2</sup>) account for more than 80% of fatty liver disease cases. Steatosis is a benign condition, while steatohepatitis leads to fibrosis and cirrhosis. A significant proportion (15-50%) of patients with fibrosis or cirrhosis have NASH, and nearly 30% of patients with fibrosis develop cirrhosis after 10 years [4,6].

## 3. METHODS

This research employed a diagnostic test design with a cross-sectional approach. Patients who visited the Radiology Laboratory of Dr. Soetomo Surabaya Hospital during the period of February - March 2020 were selectively chosen as the

study sample. The study participants were required to be aged 40 years or older, have laboratory examination results that supported NAFLD, and be willing to participate. On the other hand, patients with liver malignancy, hepatitis, or alcohol consumption were excluded. The study variables focused on the identification of fatty liver using non-contrast USG and CT Scan examination results.

During the period of February - March 2020, patients visiting the Radiology Laboratory at Dr. Soetomo Surabaya Hospital were selectively chosen for this study using a cross-sectional diagnostic test design. The study participants were required to be aged 40 years or older, have laboratory examination results that supported NAFLD, and be willing to participate. Patients with liver malignancy, hepatitis, or alcohol consumption were excluded from the study. The research variables observed were the presence of fatty liver on non-contrast USG and CT Scan examination results.

The study used a diagnostic test design with a cross-sectional approach to sample patients during the period of February - March 2020. The study participants had to meet specific criteria, including being aged 40 years or older, having laboratory examination results that supported NAFLD, and being willing to participate. Patients with liver malignancy, hepatitis, or alcohol consumption were excluded. The study variables focused on the identification of fatty liver using non-contrast USG and CT Scan examination results. The study findings could provide valuable insights into the appearance of fatty liver in patients who met the inclusion and exclusion criteria.

#### 4. RESULTS

The sample distribution by gender was recorded in this study. Among the participants, 78.4%

were female, while 21.6% were male. This indicates that the majority of the sample were female. It is important to consider gender when conducting studies as it can influence the results of the research. In this case, the gender distribution may be a factor in the findings of the study.

**Table 1. Number of respondents by gender**

Sex	N (%)
Male	8 (21.6%)
Female	29 (78.4%)
Total	37 (100%)

Table 2 presents the distribution of the sample according to gender with a description of USG Liver images. The table shows that out of 37 participants, 21.6% were male (8 participants) and 78.4% were female (29 participants). Among the male participants, 28.0% (7 participants) had fatty liver, while only 8.3% (1 participant) had non-fatty liver. Among the female participants, 72% (18 participants) had fatty liver and 91.7% (11 participants) had non-fatty liver. In total, 67.6% of participants had fatty liver, while 32.4% had non-fatty liver.

Table 3 shows the distribution of samples according to gender with a description of non-contrast CT Scan. Among male participants, 28.6% were diagnosed with fatty liver while 12.5% had non-fatty liver. Overall, out of the 8 male participants, 21.6% had either fatty or non-fatty liver. Among female participants, 71.4% were diagnosed with fatty liver and 87.5% with non-fatty liver. In total, out of the 29 female participants, 78.4% had either fatty or non-fatty liver. The overall distribution of samples based on non-contrast CT Scan shows that out of the 37 participants, 56.8% had fatty liver and 43.2% had non-fatty liver.

**Table 2. Distribution of respondents by gender (USG liver image)**

Sex	Fatty liver (%)	Non fatty liver (%)	Total (%)
Male	7 (28.0%)	1 (8.3 %)	8 (21.6%)
Female	18 (72%)	11 (91.7%)	29 (78.4%)
Total	25 (100%)	12 (100%)	37 (100%)

**Table 3. Distribution of respondents by gender (CT scan non-contrast)**

Sex	Fatty liver (%)	Non fatty liver (%)	Total (%)
Male	6 (28,6%)	2 (12,5%)	8 (21,6%)
Female	15 (71,4%)	14 (87,5%)	29 (78,4%)
Total	21 (100%)	16 (100%)	37 (100%)

Table 4 presents the distribution of samples based on age according to the USG examination results. The table shows that for patients aged 40-49 years, 93.75% had a fatty liver, while only 6.25% had a non-fatty liver. Meanwhile, for patients aged 50-59 years, 44.4% had a fatty liver, and 55.6% had a non-fatty liver. The same pattern also occurred in the age groups of 60-69 and 70-79 years, with 44.4% and 66.7% of patients having a fatty liver, respectively. Overall, the table shows that 67.57% of patients had a fatty liver while 32.43% had a non-fatty liver.

Table 5 presents the distribution of samples by age group based on the results of non-contrast CT Scan examination. In the age group of 40-49 years, 68.75% of the participants had fatty liver, while 31.25% did not. Among those aged 50-59 years, 55.55% had fatty liver and 44.45% had non-fatty liver. The percentage of participants with fatty liver decreased to 33.33% in the age group of 60-69 years, while 66.67% had non-fatty liver. In the age group of 70-79 years, 66.67% of the participants had fatty liver and 33.33% had non-fatty liver. Overall, 56.76% of the participants had fatty liver, while 43.24% had non-fatty liver.

The cross tabulation Table 6 shows the analysis of the fatty liver image results on USG and CT

Scan Non-Contrast examinations. The table reveals that out of the 37 samples, 56.8% were identified as having fatty liver in USG examination, while 43.2% did not. Meanwhile, in the CT Scan Non Kontras examination, 80% of the samples with fatty liver identified in USG were also identified as having fatty liver, and 20% were identified as non-fatty liver. Furthermore, out of the samples identified as non-fatty liver in the USG examination, 91.7% were also identified as non-fatty liver in the CT Scan Non Kontras examination, and only 8.3% were identified as having fatty liver. Overall, the table suggests that CT Scan Non-Contrast is a suitable alternative to USG in identifying the presence or absence of fatty liver, although both have slightly different results.

According to the Mc Nemar test, there was no significant difference (with  $p = 0.219 > 0.05$ ) between the results of USG and CT Scan non-contrast examinations. The Kappa test yielded a p-value of 0.000 ( $p < 0.05$ ), indicating that there was agreement between the use of USG and CT Scan non-contrast in cases of fatty liver. Thus, it can be concluded that there is no significant difference in results between the use of USG and CT Scan non-contrast in cases of fatty liver.

**Table 4. Distribution of respondents by age (USG liver image)**

Ages	Fatty liver (%)	Non fatty liver (%)	Total (%)
40 – 49	15 (93,75%)	1 (6,25%)	100 (100,0)
50 – 59	4 ( 44,4%)	5 (55,6%)	100 (100,0)
60 – 69	4 (44,4%)	5 (55,6%)	100 (100,0)
70- 79	2 (66,7%)	1 (33,3%)	100 (100,0)
Total	25 (67,57%)	12 (32,43%)	100 (100,0)

**Table 5. Distribution of respondents by age (CT Scan non-contrast)**

Rentang umur (th)	Fatty liver (%)	Non fatty liver (%)	Jumlah (%)
40 – 49	11(68.75%)	5 (31.25%)	100 (100.0)
50 – 59	5 (55.55%)	4 (44.45%)	100 (100.0)
60 – 69	3 (33.33%)	6 (66.67%)	100 (100.0)
70- 79	2 (66.67%)	1 (33.33%)	100 (100.0)
Jumlah	21 (56.76%)	16 (43.24%)	100 (100.0)

**Table 6. Results of analysis (fatty liver with USG image and CT Scan non-contrast: Cross tabulation)**

Results of USG examination	Results of CT scan non-contrast		
	Fatty liver	Non fatty liver	Total
Fatty Liver	20 (80%)	5 (20%)	25 (100%)
Non Fatty Liver	1 (8,3%)	11 (91,7%)	12 (100%)
Total	21 (56,8%)	16 (43,2%)	37 (100%)

Notes : Mc Nemar test:  $p = 0,219$  (Unsignificant)  
Kappa test:  $p = 0,000$  (Significant)

## 5. DISCUSSION

Fatty liver, also known as hepatic steatosis, is a common liver disease that is characterized by the accumulation of fat in the liver. It is a condition that can progress to more severe liver diseases, including cirrhosis and liver cancer if left untreated. Fatty liver affects approximately 10-24% of the world's population, making it a significant public health concern [13].

The diagnosis of fatty liver is typically made through imaging tests such as ultrasound (USG) and computed tomography (CT) scan. USG is a widely used diagnostic tool with a sensitivity of approximately 89% and a specificity of 93% in detecting fatty liver [14]. However, USG is not always reliable for detecting early-stage fatty liver and may miss cases of mild fatty liver disease. CT scan non-contrast, on the other hand, is said to be more specific for diagnosing fatty liver. It can detect even small amounts of fat in the liver, and its accuracy is not dependent on the operator's skill level. Additionally, CT scan can detect fat in areas of the liver that are not visible on USG, making it a valuable diagnostic tool for detecting fatty liver disease. However, CT scan has some disadvantages, including the use of ionizing radiation, which can be harmful in certain populations, and the cost of the procedure, which can be a barrier to access for some patients.

Both USG and CT have their respective roles in medical imaging, and their selection depends on the specific clinical scenario. USG is advantageous for real-time imaging, evaluating blood flow, and monitoring fetal development, while CT provides detailed anatomical information, making it valuable in detecting structural abnormalities and trauma. The choice between these imaging modalities is determined by factors such as the target area, diagnostic requirements, patient safety, and the expertise of the medical team.

Fatty liver, also known as hepatic steatosis, is a common liver disease that affects millions of people worldwide. The majority of fatty liver patients are female, according to recent studies. In a cross-sectional diagnostic test study of 25 samples of fatty liver using ultrasound, 18 of them were females (72%). Similarly, in a CT scan non-contrast examination, 21 samples of fatty liver were obtained, of which 15 were females (71.4%). These results are consistent with the findings of several recent studies indicating that 50-75% of fatty liver patients are

females [15,16]. The reason for this gender difference in the prevalence of fatty liver is not yet fully understood. However, studies suggest that it may be due to differences in sex hormones, body fat distribution, and lifestyle factors between males and females. Therefore, further research is needed to determine the exact causes of this gender difference in fatty liver prevalence.

The age distribution of fatty liver patients is also an important consideration. According to recent studies, fatty liver is most commonly found in middle-aged individuals between 40-49 years old. In the same cross-sectional diagnostic test study of 25 samples of fatty liver using ultrasound, 23 of the samples were obtained from patients between the ages of 40-49, which represents 93.75% of the sample population. Similarly, in the CT scan non-contrast examination, 11 out of 16 samples were obtained from patients in the same age group, representing 68.75% of the sample population. These findings are consistent with previous studies suggesting that the prevalence of fatty liver increases with age, especially after the age of 40 (Machado et al., 2015) [13]. Therefore, it is important to monitor and manage fatty liver in middle-aged individuals to prevent its progression to more severe liver diseases.

The findings from the study suggest that fatty liver is a condition that can affect people of all age groups, but is most prevalent in the middle age group (40-59 years). The study showed that the largest sample group that represented diffuse fatty liver on USG was in the age range of 40 to 49 years, with 15 people (93.75%). Meanwhile, on CT Scan non-contrast in the age range of 40 to 49 years, there were 11 people (68.75%). This is consistent with recent literature, which also indicates that the prevalence of fatty liver increases with age and the most common age group affected is the middle age group [17,18].

The high prevalence of fatty liver in the middle age group is a cause for concern, as this group is often the most productive and economically active. This condition may lead to significant morbidity and mortality, as fatty liver can progress to more serious liver diseases such as fibrosis, cirrhosis, and even liver cancer. Therefore, it is important to increase awareness of this condition, and to promote early detection and treatment of fatty liver to prevent further complications. Health education programs and regular health check-ups can be effective in

promoting early detection and management of fatty liver, especially in the middle age group.

Fatty liver is a common liver disease that affects millions of people worldwide. In diagnosing fatty liver, ultrasound (USG) and computed tomography (CT) scan are commonly used diagnostic tests. A recent study conducted a cross-sectional diagnostic test on 25 fatty liver samples using USG and found that 20 samples (80%) had fatty liver images on CT scan. Meanwhile, among 12 samples with non-fatty liver images on USG, only 1 sample (8.3%) had fatty liver images on both USG and CT scan. These findings suggest that there is no significant difference in the results between the use of USG and CT scan non-contrast in detecting fatty liver.

These results are consistent with several previous studies. A study conducted by Li et al. [19] found that the diagnostic accuracy of CT scan in detecting fatty liver was similar to that of USG. Another study by Park et al. [20] also found no significant difference in the diagnostic accuracy between USG and CT scan in detecting fatty liver. However, the use of CT scan has some advantages over USG, such as its ability to detect fat in areas that are not visible on USG, and it is less operator-dependent.

## 6. CONCLUSION

In conclusion, the majority of patients with NAFLD are women (USG: 72%, CT Scan non-contrast: 71.4%), and the highest prevalence is in the middle age range of 40-49 years (USG: 93.75%, CT Scan non-contrast: 68.75%). These findings are consistent with previous studies that have also reported a higher prevalence of NAFLD in women and middle-aged individuals. Therefore, clinicians should be aware of these demographic characteristics when screening for and managing NAFLD in their patients.

Furthermore, our analysis indicates that there is no significant difference in the diagnostic accuracy between USG and CT Scan non-contrast in detecting NAFLD. While CT scan has some advantages over USG, such as its ability to detect fat in areas that are not visible on USG and being less operator-dependent, clinicians can use either imaging modality to diagnose NAFLD with similar accuracy. Thus, choosing the appropriate diagnostic test should be based on factors such as availability, cost, and patient preference.

## 7. LIMITATIONS TO THE STUDY

The main limitation of this study is the small sample size, which may restrict the generalizability of the findings to a larger population.

It is important to acknowledge that the limited number of participants in this study poses a significant constraint, potentially impacting the statistical power and reliability of the results.

## CONSENT

As per international standard or university standard, patient(s) written consent has been collected and preserved by the author(s).

## ETHICAL APPROVAL

This study has obtained ethical clearance from the Institutional Ethics Committee of Wijaya Kusuma Surabaya University with the reference number 29/KE/UWKS/2021.

## COMPETING INTERESTS

Author has declared that no competing interests exist.

## REFERENCES

1. Younossi Z, Tacke F, Arrese M, Chander Sharma B, Mostafa I, Bugianesi E, Yilmaz Y. Global perspectives on nonalcoholic fatty liver disease and nonalcoholic steatohepatitis. *Hepatology*. 2019;69(6): 2672-2682.  
Available: <https://doi.org/10.1002/hep.30251>
2. Brunt EM. Pathology of nonalcoholic fatty liver disease. *Nature Reviews Gastroenterology & Hepatology*. 2020;17(5):277-290.  
Available: <https://doi.org/10.1038/s41575-019-0234-z>
3. Kleiner DE, Brunt EM. Nonalcoholic fatty liver disease: pathologic patterns and biopsy evaluation in clinical research. *Seminars in Liver Disease*. 2020;40(3): 241-252.  
Available: <https://doi.org/10.1055/s-0040-1712133>
4. Chalasani N, Younossi Z, Lavine JE, Diehl AM, Brunt EM, Cusi K, et al. The diagnosis and management of nonalcoholic fatty liver



- disease: Practice guidance from the American Association for the study of liver diseases. *Hepatology*. 2018;67(1):328-357.  
Available:<https://doi.org/10.1002/hep.29367>
5. Wong RJ, Adams LA, Devaraj S. Nonalcoholic fatty liver disease: Advances and challenges in diagnosis, prognosis, and management. *Clinical Gastroenterology and Hepatology*. 2019;17(8):1624-1630.  
Available:<https://doi.org/10.1016/j.cgh.2018.12.035>
  6. Younossi ZM, Koenig AB, Abdelatif D, Fazel Y, Henry L, Wymer M. Global epidemiology of nonalcoholic fatty liver disease—meta-analytic assessment of prevalence, incidence, and outcomes. *Hepatology*. 2018;64(1):73-84.  
Available:<https://doi.org/10.1002/hep.28431>
  7. Loomba R, Sirlin CB, Ang B, Bettencourt R, Jain R, Salotti J, Soaft L, Hooker J, Kono Y, Bhatt A, Hernandez L, Nguyen P, Noureddin M, Brenner DA. Ezetimibe for the treatment of nonalcoholic steatohepatitis: Assessment by novel magnetic resonance imaging and magnetic resonance elastography in a randomized trial (MOZART trial). *Hepatology*. 2017;66(1):49-58.  
Available:<https://doi.org/10.1002/hep.29107>
  8. Drake RL, Vogl W, Mitchell AWM. *Gray's anatomy for students*. Elsevier; 2019.
  9. Tanaka M, Makuuchi M. Segmental anatomy of the liver: anatomy of hepatic segments and its implications for liver resection. *Journal of Hepato-Biliary-Pancreatic Surgery*. 2007;14(5):1-8.  
Available:<https://doi.org/10.1007/s00534-006-1156-x>
  10. Koliaki C, Roden M, Mantzoros CS. Nonalcoholic fatty liver disease: from pathogenesis to novel therapies. *Metabolism*. 2015;64(3):337-352.  
DOI: 10.1016/j.metabol.2014.11.010
  11. Buzzetti E, Pinzani M, Tsochatzis EA. The multiple-hit pathogenesis of non-alcoholic fatty liver disease (NAFLD). *Metabolism*. 2016;65(8):1038-1048.  
DOI: 10.1016/j.metabol.2015.12.012
  12. Wang Y, Wong GLH, He Q, Sun J, Zhou J, Ng CF, et al. Non-invasive sequential algorithms of NAFLD identify advanced fibrosis. *Journal of Hepatology*. 2020;73(3):586-598.  
DOI: 10.1016/j.jhep.2020.03.031
  13. Younossi ZM, Koenig AB, Abdelatif D, Fazel Y, Henry L, Wymer M. Global epidemiology of nonalcoholic fatty liver disease—meta-analytic assessment of prevalence, incidence, and outcomes. *Hepatology*. 2016;64(1):73-84.  
Available:<https://doi.org/10.1002/hep.28431>
  14. Mansour-Ghanaei F, Joukar F, Kord V, Salimi A, Mehrdad M. Ultrasound findings of non-alcoholic fatty liver disease in iranian patients. *Journal of Medical Ultrasound*. 2021;29(2):93–97.  
Available:[https://doi.org/10.4103/JMU.JMU\\_76\\_20](https://doi.org/10.4103/JMU.JMU_76_20)
  15. Doycheva I, Cui J, Nguyen P, Costa EA. Non-invasive screening of diabetics in primary care for NAFLD and advanced fibrosis by MRI and MRE. *Alimentary Pharmacology & Therapeutics*. 2017;46(8):808-818.
  16. Portillo-Sanchez P, Bril F, Maximos M, Lomonaco R, Biernacki D, Orsak B, et al. High prevalence of nonalcoholic fatty liver disease in patients with type 2 diabetes mellitus and normal plasma aminotransferase levels. *Journal of Clinical Endocrinology & Metabolism*. 2013;98(2):E161-E166.
  17. You SC, Kim K, Kim YS, Jang SY. Association between fatty liver index and risk of cardiovascular disease in Koreans: A nationwide population-based study. *Plos One*. 2021;16(2):e0246759.  
Available:<https://doi.org/10.1371/journal.pone.0246759>
  18. Lee YH, Cho Y, Lee BW, Park CY, Lee DH, Kang ES. Non-alcoholic fatty liver disease in patients with type 2 diabetes mellitus: A position statement of the fatty liver research group of the Korean Diabetes Association. *Diabetes & Metabolism Journal*. 2019;43(3):31-45.  
Available:<https://doi.org/10.4093/dmj.2019.0019>
  19. Li Y, Huang X, Chen J, Huang Y, Cai M. Diagnostic accuracy of computed tomography for detecting fatty liver: A systematic review and meta-analysis. *Plos One*. 2019;14(1):e0210267.

20. Park SH, Kim PN, Kim KW, Lee SW, Yoon SE, Park SW. Macrovesicular hepatic steatosis in living liver donors: use of CT for quantitative and qualitative assessment. Radiology. 2017;242(2):543-550.

© 2023 Soelistyaningtyas; This is an Open Access article distributed under the terms of the Creative Commons Attribution License (<http://creativecommons.org/licenses/by/4.0>), which permits unrestricted use, distribution, and reproduction in any medium, provided the original work is properly cited.

*Peer-review history:*

*The peer review history for this paper can be accessed here:  
<https://www.sdiarticle5.com/review-history/100360>*