



Intracystic Papillary Carcinoma in the Mammary Gland of She-Camel (*Camelus dromedaries*), Sudan

A. M. Abeer^{1*}, A. M. Zakia², K. B. Mohammed² and E. A. Muna¹

¹Department of Bacteriology, Central Veterinary Research Laboratory, El-Amart, P.O Box 8068, Khartoum, Sudan.

²Department of Pathology, Central Veterinary Research Laboratory, El-Amart, P.O Box 8068, Khartoum, Sudan.

Authors' contributions

This work was carried out in collaboration between all authors. All authors read and approved the final manuscript.

Article Information

Editor(s):

(1) Dr. Krishnangshu Bhanja Choudhury, Assistant Professor, Department of Radiotherapy, R.G. Kar Medical College and Hospital, Kolkata, India.

Reviewers:

(1) Tariq Namad, University of Cincinnati Medical Center, USA.

(2) Arthur N. Chuemere, University of Port Harcourt, Nigeria.

Complete Peer review History: <http://www.sdiarticle3.com/review-history/46654>

Original Research Article

Received 28 September 2018

Accepted 24 January 2019

Published 11 March 2019

ABSTRACT

Aims of the Study: Survey of udder disorders over one year to investigate the histopathological lesions of tumors in camel (*Camelus dromedarius*).

Place of Study: The study was undertaken in the Department of Pathology, Central Veterinary Research Laboratory, Ministry of Animal Resource and Fisheries, Khartoum, Sudan.

Study Design: 45 tumors of camel udder tissues were obtained from Tumbool abattoir Al-Gazeera State; the gross and histopathological lesions were studied.

Methodology: The macroscopic pictures of samples were reviewed and described, then histopathological lesions were studied using H&E stain. Lastly immunohistochemical staining was done using estrogen, progesterone antibodies and CytoKeratin 5/6.

Results: A survey over a one year was done, 45 tumours were diagnosed, of which 23 were malignant. Only one tumour had features suggestive of intracystic papillary carcinoma (IPC).

Conclusion: To the best of our knowledge this may be the first intra cystic papillary carcinoma reported in the udder of a dromedary worldwide.

Keywords: Intracystic papillary carcinoma; immuno-stain mammary gland; the dromedary-she-camel; Sudan.

1. INTRODUCTION

Neoplasms of the mammary glands occur in all animal species. The prevalence of tumor in carnivores and herbivores and between captive and wild carnivores is quite different [1]. This neoplasm is the most common in bitches; it ranks third after skin and lymphoma in queens [2]. The available literature on papillary cystadenoma in food producing animal is rare [3]. The occurrence of intracystic papillary carcinoma in herbivores is rare.”

There is an only single reported case of multicentric papillary cystadenoma in a cow [4]. To the best of our knowledge this may be the first of intra cystic papillary carcinoma report in the udder of dromedary worldwide.

2. MATERIALS AND METHODS

2.1 Case History

During a survey of udder affections of slaughtered she-camels was conducted at Tumboul slaughterhouse, El-Gezira, State, Sudan. A thirteen-year-old, non-pregnant, non-lactating local eco-type she-camel with a history of chronic incurable udder affection was examined at slaughter. She originates from North Drafur State. The udder was slightly swollen, hard in consistency and the teat of the left hind quarter was distended approximately 2-3 times the normal size, completely obstructed canal. On cut section the udder was lobulated, grayish-white with arborescent growth with irregular extensive branches hanging from the body of the udder filling and occluding the teat canal.

2.2 Histopathological Method

Tissue specimens from udder were fixed in 10% formalin, processed routinely in paraffin wax and 5-6 μ sections were cut and stained with haematoxylin and eosin (H&E).

For tumor Immunohistochemistry using dextrane polymer_hrp for estrogen and progesterone receptor was done, and Ck 5&6 according to Histopathology Department of Radiation and Isotopes Center Khartoum.

3. RESULTS

At slaughter, the udder was slightly swollen, hard in consistency and the teat of the left hind quarter was distended approximately 2-3 times the

normal size, and its canal was completely obstructed. On cut section the udder was lobulated, grayish-white with arborescent growth with irregular extensive branches hanging from the body of the udder filling and occluding the teat canal. Small multi-papillae forming bunch of grape-like structures were projecting from these arborescent growths (Fig. 1).

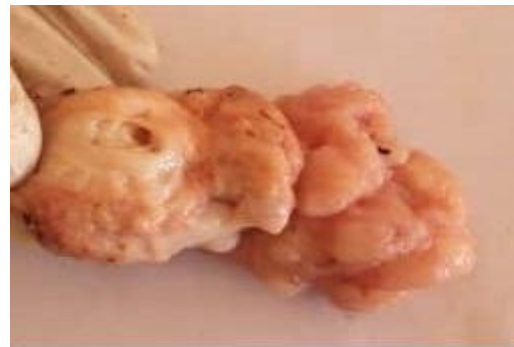

Fig 1: Macroscopic appearance of the tumor. A formalin fixed piece of the tumor showed a lobular pattern delineated by fibrous septa.

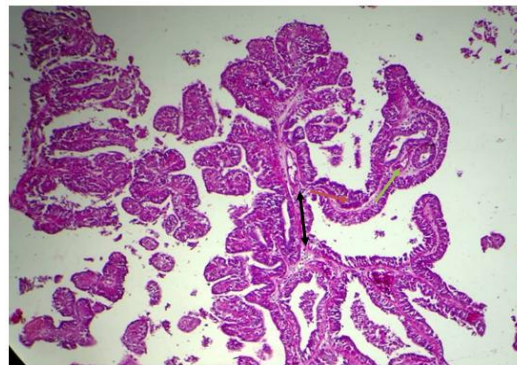


Fig 2: Intracystic papillary carcinoma, Note complex fibrovascular core with primary (black), secondary (red) and tertiary (green) branches H&E x10.

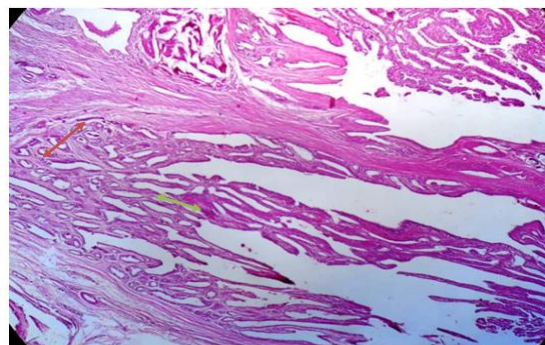


Fig 3: Intracystic papillary carcinoma Note, Early tumor transformation (green arrow) or infiltrated in apparently normal glandular tissues (red arrow) H&E x4.

Histopathologically, the most prominent finding was complete obliteration of normal udder tissue which was replaced by multilineoplastic masses entrapped in multilocular cyst or dilated ducts. The papillary fronds infiltrated into primary, secondary and tertiary branches (Fig. 2). Tumor invasion of the cyst wall and the lymphatics were detected. The lobules bordering the neoplastic masses presented areas of early tumor transformation with the papillary fronds appeared to be emerging from, or infiltrating into apparently normal secretory acini (Fig. 3). Each cyst was lined with one layer of flat to low cuboidal epithelial cells surrounded by fibrous tissue, stroma that varied in size from narrow to moderately wide in size. Each of the neoplastic masses composed of densely packed papilliferous fronds supported by fibrovascular core that appeared to be projected from the cyst wall (Fig. 4). Some papillary projections were covered with one or multi-layers of cuboidal to low columnar epithelial cells. On the other hand exophytic intracystic papillary fronds covered with pleomorphic poorly orientated undifferentiated epithelial cells were regularly encountered together with stratification of the nuclei which formed irregular clusters. The nuclei were vesicular or clear with the ground-glass appearance. Dystrophic calcification was encountered in the epithelium and connective component of neoplastic masses. Moderate mononuclear cells reaction was observed in stromal connective tissue.

Immunostain for estrogen and progesterone were both negative while the ck 5/6 was highly positive (Fig. 5).

4. DISCUSSION

In the current study the masses were diagnosed as intracystic papillary carcinoma (IPC) based on the presence of papillary frond-forming pattern supported by fibrovascular stalk, which were considered as a diagnostic feature of papillary carcinoma [5,6,7,8]. These changes were consistent with those previously described for IPC in bitches [9]; a cow [4]; zoo animals [10] and in the man [6,11,12]. The neoplastic masses were projected in cystic cavity thus giving pathognomonic feature of intracystic neoplasm, this is in line with [6,11] who stated that if intracystic component is present the tumor it should be classified as intracystic papillary carcinoma.

Based on the aforementioned morphological features and the relatively poorly differentiated plastic cells with cellular and nuclear pleomorphism and tumor invasion in cyst wall and lymphatics vessels, The tumor was described as carcinoma or malignant. This is in agreement with [2,13] who considered the cellular anaplasia and tumor invasion as a hallmark for malignancy. Furthermore, presences of empty or vesicular nuclei are considered as classic nuclear morphologic feature of papillary carcinoma [8,14,15]. Other authors [16,11], however, reported that invasion of papillary carcinoma occurs infrequently, as early small focus of stromal invasion and almost at the periphery of the lesion. Gatchell reported intracystic papillary carcinoma invasion in cyst wall, in vascular and lymphatic veins [17].

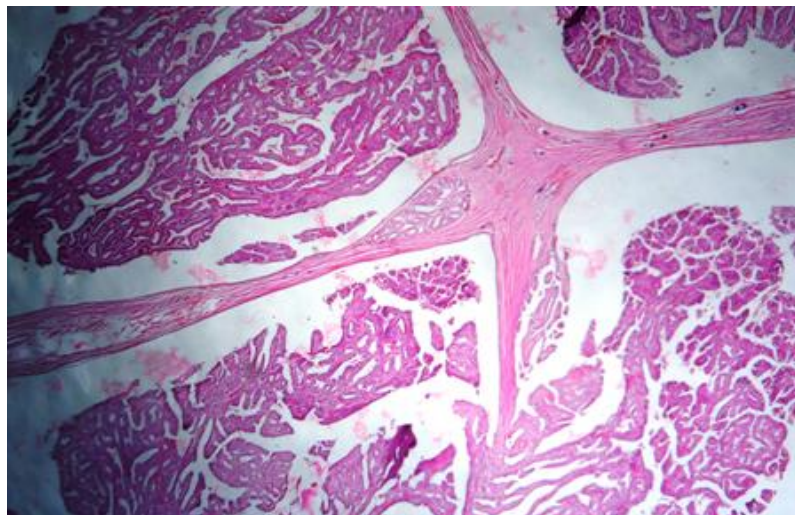


Figure 4: lower view of Intracystic papillary carcinoma. Note, multiple neoplastic masses utrapped in multilocular cystic spaces, the fibrovascular stak projecting from the cyst wall, cyst wall invasion by tumor H&E.

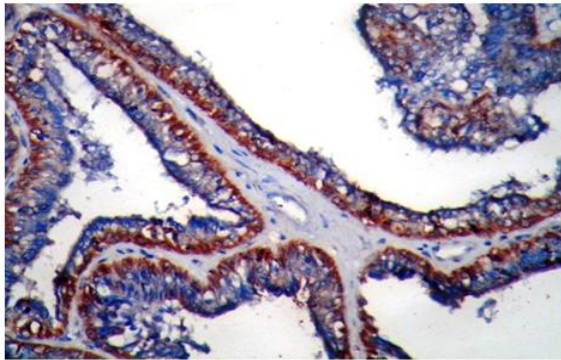


Fig 5: Udder of she camel with intracystic papillary carcinoma and positive for ck 5/6 Note, brown color, immunostain X40.

Morphologically, IPC has the features of intraductal papillary carcinoma (IDPC) in situ. These authors stated that the differentiation between them may be arbitrary [18]. However, Cater described IDPC in situ as non-invasive carcinoma extending into the small and medium sized ducts throughout the breast [6]. On the other hand, another opinion was suggested, that if the epithelium of the papillary carcinoma has features diagnostic for intra-ductal component the tumor should be classified as intra-ductal [12].

Our study showed that certain lobules adjacent to the tumor revealed coexistence of both papillary fronds and apparently normal glandular tissue. It is difficult to draw any conclusion whether the papillary fronds emerging from, or infiltrating into, apparently normal udder tissue. Other investigators [19,20] are of the opinion that adenocarcinomas Tubular or papillary, arise from the alveolar epithelium. Furthermore, Moulton suggested that papilliferous epithelium proliferations develop from the alveolar tissue within lobule, interlobular duct or teat sinus. Papillae were formed, when the ductules or alveoli become dilated and separated by thin stromal septa. When the septa break, the lobule is converted into single cyst with intraluminal papillae [19].

In lamb immune-histochemistry revealed the ductal epithelium to be positive for pan cytokeratin (AE1/AE3) and loose fibrovascular stroma was positive for vimentin and basal cells covering the ductal epithelium of alpha-smooth-muscle actin. Immuno-staining for the estrogen and progesterone receptors was negative may have resulted from a lack of cross reactivity to the ovine species of antibodies used. A diagnosis of mammary fibroadenoma was made based on the histological and immunohistochemical findings [21]. In the mixed mammary tumor in

camel, they found papillary section was moderate positive result for estrogen receptor and negative progesterone, while the fibroadenoma section was negative for both receptors [22].

5. CONCLUSIONS

To our knowledge this is the first time that the tumor cases reported in the field and found to be a problem in the udder of the camels.

Intracystic papillary carcinoma IPC is described, the histopathology in one of best method for diagnoses tumor.

Further research should be tackled in order to determine the role of the neoplastic masses in the disease prevalence for better epidemiological consideration.

CONSENT

It is not applicable.

ETHICAL APPROVAL

All authors hereby declare that all animals experiments have been examined and approved by the appropriate ethics committee and have therefore been performed in accordance with the ethical standards.

ACKNOWLEDGEMENTS

The Authors wish to thank the Director of Central Veterinary Research Laboratory for permission to publish this manuscript. The technical assistance of Omer. F, Nageeb. M and Omiema, H is highly appreciated. Nada Salih Osman, Senior of histopathology department in radiation and isotopes center Khartoum for their technical assistance.

COMPETING INTERESTS

Authors have declared that no competing interests exist.

REFERENCES

1. Munson L, Moresco A. Comparative pathology of mammary gland cancers in domestic and wild animals. J. Breast Diseases IOS Press. 2007;28:7-21.
2. Misdrop W. Tumors of the mammary glands. In: Tumors of Domestic Animals, 4th Edition, Meuten, D. J. (Ed), Blackwell Publisher. 2002;575-606.

3. Povey RC, Osborne AD. Mammary gland neoplasia in the cow. *Vet Pathol.* 1969;6:502-512.
4. Reimer JM, Sweeney RW, Saik J. Multicentric papillary cystadenoma in the udder of a cow. *J.A.V.M.A.* 1988;192:1297-1298.
5. Stewart FW. Tumor of the breast. Atlas of tumor pathology section IX- Fascicle 34, Armed Forces Institute of Pathology Washington D.C. 1950;F34-18-F34-114.
6. Cater D, Orr SL, Merino MJ. Intracystic papillary carcinoma of the breast. *Cancer.* 1983;52:14-19.
7. Soo MS, Williford ME, Walsh R, Bentley RC, Kornguth P. Papillary carcinoma of the breast, imaging findings. *A.J.R.* 1995;164:321-326.
8. Rosen PP. Papillary carcinoma. In: *Rosen Pathology, Philadelphia, Pa.* Lippincott-Raven. 1997;335-354.
9. Misdrop W, Colchin E, Hampe JF, Anne Jabara AG, Sandersleben V. Canine malignant mammary tumor II. Adenocarcinoma, solid carcinoma and spinal cell carcinoma. *Vet. Pathol.* 1972;9:447-470.
10. McAloose D, Munson L, Naydan DK. Histologic features of mammary carcinomas in zoo field treated with Melengestrol acetate (MgA) contraceptive. *Vet. Pathol.* 2007;44:320-326.
11. Liberman J, Feng TL, Susnik B. Case 35: Intracystic papillary carcinoma with invasion. *Radiology.* 2001;219:781-784.
12. Muttarak M, Somwangrasert A, Chaiwun B. Intracystic papillary carcinoma of the breast. *Biomed. Imag. Inter. J.* 2005;1:1-3.
13. Cheville NF. Neoplasia. In: *Cell Pathology*, Ed. by Cheville. N. F. Iowa State University Press, Ames. 1976;266-322.
14. Khan AR, Abu-Eshy SA. Variants of papillary carcinoma of the thyroid. Experience at Asir Centre Hospital. *J. R. Coll. Surg. Edinb.* 1998;43:20-25.
15. Karmegama K, Takami H, Miyajima K, Miura T, Hosoda Y, Ito K. Papillary carcinoma occurring with an adenomatous goiter of thyroid gland in cowden's disease. *Endocrine Pathol.* 2001;12:73-76.
16. Sliver S, Askin F. True papillary carcinoma of the lung. A distinct clinicopathologic entity. *Am. J. Surg. Pathol.* 1997;21:43-51.
17. Gatchell FG, Dockerty MB, Clagett OT. Intracystic carcinoma of the breast. *Surg. Gynecol. Obstet.* 1958;106:347-352.
18. Hampe JF, Misdrop W. Tumors and dysplasia of the mammary glands. *Bull. WHO.* 1974;50:111-133.
19. Moulton JE. Tumor of the mammary gland. *Tumors of the Domestic Animals, 2nd Edition*, Moulton, J. E. (Ed), University of California Press. Berkeley, C. A. 1987;350.
20. Benjamin SA, Lee AC, Sandurs WJ. Classification and behavior of canine mammary epithelium neoplasm based on life span observation in Beagles. *Vet. Pathol.* 1999;36:423-436.
21. Gulbahar MY, Guvenc T, Yarim M, Kabak YB, Sozgen Y. Mammary fibroadenoma in a lamb. *J. Vet. Sci.* 2007;8:423-425.
22. Abeer AM, Zakia AM, Muna EA, Afaf EA. Incidence of multiple mammary tumors and fibroadenoma in pathological study of udder affections in camel (*Camelus dromedarius*). *JCTI.* 2016;4(1):1-7.

© 2019 Abeer et al.; This is an Open Access article distributed under the terms of the Creative Commons Attribution License (<http://creativecommons.org/licenses/by/4.0>), which permits unrestricted use, distribution, and reproduction in any medium, provided the original work is properly cited.

Peer-review history:
The peer review history for this paper can be accessed here:
<http://www.sdiarticle3.com/review-history/46654>