



A Case Report of ChAdOx1 nCoV- 19 Corona Virus Recombinant Vaccine Related Granuloma Annulare

S. Swetha Shri ^{a#} and Jayakar Thomas ^{a*†}

^a Department of Dermatology, Chettinad Hospital and Research Institute, Kelambakkam, Chennai, India.

Authors' contributions

This work was carried out in collaboration between both authors. Both authors read and approved the final manuscript.

Article Information

DOI: 10.9734/JPRI/2021/v33i51B33533

Editor(s):

- (1) Dr. Giuseppe Murdaca, University of Genoa, Italy.
(2) Dr. Amal Hegazi Ahmed Elrefaei, Hot Lab and Waste Management Center, Atomic Energy Authority, Egypt.
(3) Dr. N. Alyautdin Renad, Scientific Centre for Expert Evaluation of Medicinal Products, Russia.

Reviewers:

- (1) Katarzyna Rygiel, Medical University of Silesia (SUM), Poland.
(2) Kshitij Karki, Purbanchal University, Nepal.
(3) Natasha Simonovska, Sts Cyril and Methodius University, North Macedonia.
(4) A. Priyadarshini, SRM Institute of Science and Technology, India.
(5) Blego Sedionoto, Mulawarman University, Indonesia.

Complete Peer review History, details of the editor(s), Reviewers and additional Reviewers are available here:
<https://www.sdiarticle5.com/review-history/76523>

Received 21 October 2021

Accepted 21 November 2021

Published 26 November 2021

Case Study

ABSTRACT

Background: Granuloma annulare (GA) is a benign, self-limiting inflammatory skin condition of unknown origin that may occur following multiple etiological triggers. GA incited secondary to vaccinations has been rarely reported in the medical literature. The COVID-19 pandemic has introduced extensive global immunization against the SARS-COV-2 virus, bringing a gamut of vaccine-related complications. We elucidate a case report of the spontaneous eventuality of GA following *ChAdOx1 nCoV-19 Corona Virus Recombinant Vaccine*.

Case Report: A healthy 26-year male presented with a one-week history of asymptomatic single, flesh-pink patch with a raised margin over his left ventral forearm. On close examination, the margin of the lesion had multiple annularly arranged papules. Biopsy of lesion was done, and histopathology revealed numerous palisading granulomas in the dermis consistent with findings of localized GA. The patient was managed with once-daily external application high potent topical

[#] Resident;

[†] Professor & Head;

*Corresponding author: E-mail: jayakarthomas@gmail.com;

corticosteroids, which was used intermittently by the patient. However, the lesion showed spontaneous resolution in one month.

Conclusion: Identifying *ChAdOx1 nCoV- 19 Vaccine*-related adverse events following its first dose is paramount, as evidence of the proportion of local or systemic severe cutaneous adverse skin reaction (SCAR) on subsequent dosing is a paucity. A more extensive systematic review corroborating SCARs and safety profile following immunization with *ChAdOx1 nCoV-19 Vaccine* prevails to be the need of the hour.

Keywords: *Granuloma annulare; skin condition; COVID-19; vaccine.*

1. INTRODUCTION

Granuloma annulare (GA) is a benign, idiopathic, self-limiting inflammatory skin condition commonly reported following trauma, insect bites, viral infections, and malignancy [1,2]. Few cases describe the spontaneous occurrence of granuloma annulare following vaccinations. With the ongoing extensive global immunization program against the SARS-CoV-2 virus, global distribution of 7.41 billion doses has been administered that covered 51.5% of the world population to have at least one dose of COVID-19 vaccine [3]. However, anecdotal reports on the cutaneous adverse reactions following COVID-19 immunization form lacunae in their early diagnosis and active medical management. Here, we describe a case of GA-like eruption following *ChAdOx1 nCoV- 19 Corona Virus Recombinant Vaccine* in a young Indian male who has no medical history nor allergies.

2. CASE REPORT

A 26-year-old male, otherwise healthy software professional, presented with a one-week history of a single lesion over his left forearm. His skin lesions were neither itchy nor painful. He has no personal or family history of skin diseases or auto immune conditions. His recent medical history includes the first dose of COVID-19 immunization ten days ago injected on his left deltoid. Prior to vaccination, he had no symptoms suggestive of COVID-19 disease. Physical examination revealed a solitary well-demarcated, annular, erythematous plaque with raised margins over the ventral aspect of his left forearm. On closer inspection, the margin of the lesion had multiple flesh-pink pinhead papule's, with a regressing pattern towards the center. The patient shared a photographed Figure of the same lesion taken on day 1 of its appearance, showing a smaller, flesh-pink patch with a raised and irregular margin with central hyperpigmentation. A 4mm punch biopsy from the lesion revealed discrete areas of well-circumscribed central necrobiotic collagen

surrounded by a palisade of histiocytes, multinucleate giant cells and peri-vascular lymphocytes mid-dermis consistent with necrobiotic palisading granulomas. The patient was diagnosed with localized GA following COVID-19 immunization with *ChAdOx1 nCoV-19 Corona Virus recombinant vaccine*. The patient was reassured about the benign nature of the lesion and was initiated with topical mometasone furoate cream with follow-up after ten days; Patient came for review after one month, with a history of discontinuation of treatment within ten days and partial improvement of lesions which eventually resolved spontaneously at 1 month from its first appearance.

3. DISCUSSION

Granuloma annulare is an idiopathic granulomatous dermatosis that commonly presents as asymptomatic, self-limiting papular eruption [4]. With a higher incidence in children and young adults, GA is approximately twice as common in females than males [1,5]. The lesions are usually found over the arms, legs, hands, and feet but may rarely present over the palms, penis, ears and periocular area. The lesions' morphology is in accordance with the clinical subtypes, namely, generalized, localized, linear, perforating, and subcutaneous [1,2,4].

In up to 15% of cases [1], generalized GA is described by the presence of 10 or more lesions or widespread plaques [2]. Patients reported with hundreds of discrete or confluent papules are not uncommon. Lesions of localized GA are common over the dorsum of the hands or feet arranged in a distinctive annular configuration showing large, slightly erythematous patches with a palpable margin on which scattered papules may subsequently arise. Perforating GA seen in 5% GA cases show tender, umbilicated lesions in a localized distribution, rarely may be generalized [1,4]. The rarest clinical variant of GA, namely subcutaneous GA presents with subcutaneous nodules, seen especially in children [1] having

close clinical resemblance with rheumatoid nodules, although there is no history of arthritis and normal serology for rheumatoid factor, anti-neutrophilic cytoplasmic antibody (ANCA), anti-nuclear antibodies (ANA) and anti-citrullinated protein (anti-CCP) antibody.

Pathogenesis of GA is based on alternating views of immunoglobulin-mediated vasculitis and delayed-type hypersensitivity response to an unknown antigen [1,6,7]. The cell-mediated immune response appears to be marked with prominent activated helper T cells. The exact mechanism by which GA is triggered in our patients is unknown. Immunological activation following vaccination may explain the presence of activated T-cells in the lymphocytic infiltrate in the palisading granulomas. There is a lesser possibility of traumatic inoculation hypothesis, as the site of granuloma formation is distant and hence less convincing [8].

Histopathology of GA is characteristic of necrobiosis and granuloma formation and abundant mucin deposition involving the dermis and subcutis. The term 'necrobiosis' is used to describe tissue death and its simultaneous but inadequate replacement by viable tissue. Four distinctive histological patterns are observed in

GA, namely infiltrative (interstitial) pattern, palisading granuloma pattern, and an epithelioid nodule (sarcoidal granuloma, mixed) pattern, are known [1]. GA shows characteristic palisading granuloma, a pattern exemplified by stacked epithelioid histiocytes aligned around a central focus of mucin [2]. In some instances, histiocytes that are seen as a foci within the dermis can be distributed interstitially as strands, cords, or columns in other foci, i.e., between bundles of collagen. Synthesis of types I and III collagen also occur as a reparative response. Necrobiosis lipoidica is a common differential diagnosis of GA shows pan-dermal inflammation, linear arrays of histiocytes surrounding necrobiotic collagen and abundant plasma cells [9]. The presence of mucin and the absence of asteroid bodies or other giant cell inclusions also less favors sarcoidosis [2]. The lesions do not display scaling and are not accompanied by vesicles or pustules, which helps distinguish GA from tinea corporis [10]. In addition, hyphae can be visualized in a potassium hydroxide preparation from a suspected lesion tinea corporis and not in a lesion of GA [10]. Hansen's disease is less likely in the absence of anaesthesia in the lesion and/or a normal peripheral nerve examination, especially in endemic regions of leprosy.

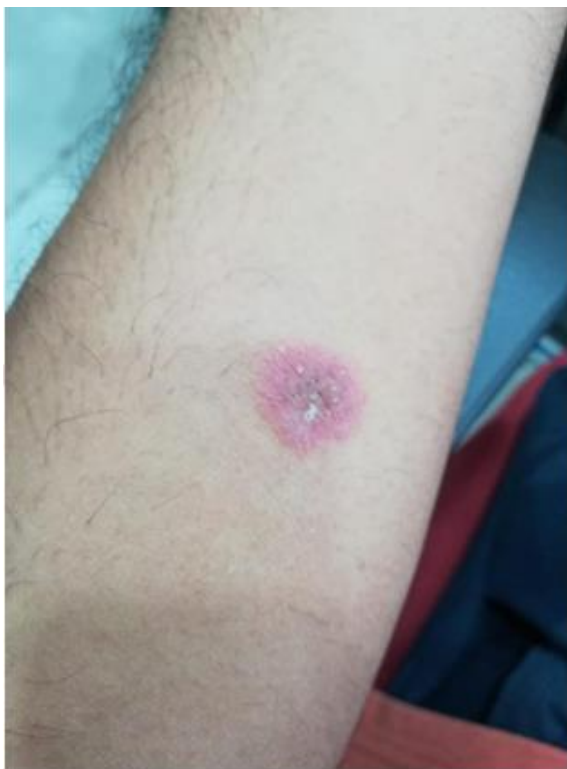

Fig. 1. Lesion seen on day 1 of appearance

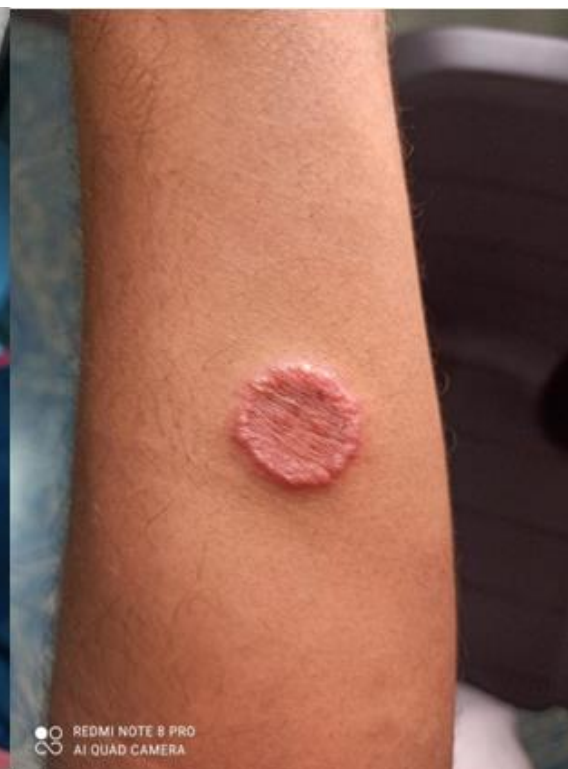

Fig. 2. Lesion as seen after one week

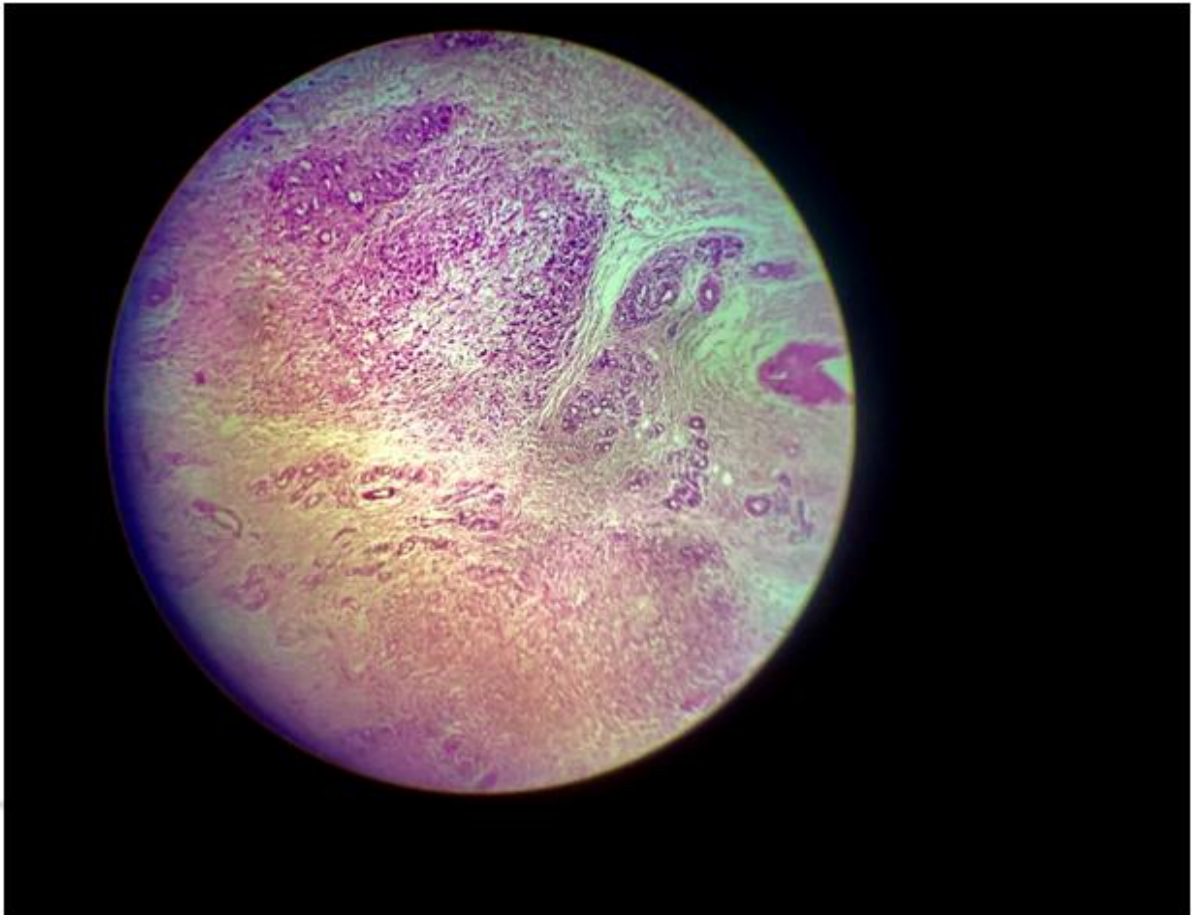


Fig. 3. Histopathology of the lesion shows characteristic palisading granulomas in the mid-dermis consistent with granuloma annulare

Several vaccines have been reported to trigger GA [5]. Bacillus Calmette-Guérin (BCG) vaccine has been most frequently reported [4], followed by the hepatitis B vaccine, influenza vaccine, tetanus and diphtheria-tetanus toxoid vaccine and pneumococcal vaccine [11]. GA after SARS-CoV-2 vaccination has not been previously described. Most cases GA following immunization with any of the above have commonly occurred in young patients, probably because the frequency of vaccination was higher at a younger age as a part of routine immunization. However, owing to the gravity of the COVID-19 pandemic situation, there is extensive immunization among adults and paediatric population. This expands the opportunity of identifying various complications that occurs post-COVID-19 immunization. Wide spectrum of vaccines formulations are in the conduit against COVID-19 disease are based upon inactivated or live attenuated viruses, protein sub-unit, virus-like particles (VLP), viral vector (replicating and non-replicating), DNA,

RNA, nanoparticles, etc. with each exhibiting unique merits and demerits [12].

According to WHO: "vaccine must provide a highly favourable benefit-risk contour; with high efficacy, only mild or transient adverse effects and no serious ailments" [13]. The *ChAdOx1 nCoV-19 Vaccine* used by our patient is a recombinant vaccine based on viral vector technology scheduled as two doses injected intramuscularly at 0.5ml. The Indian government has recommended that the time interval between the 1st and 2nd dose should be between 12-16 weeks. The most commonly reported adverse reactions to COVID-19 vaccinations are usually milder, transient, and widely acceptable over time [14].

4. CONCLUSION

Vaccine hesitancy and literacy pose significant challenges for the success of the ongoing immunization program. The general people

should be aware of the minor side effects, manageable with some symptomatic treatment. The challenge of meeting the public's expectations towards accepting COVID-19 vaccines is critical to counter this pandemic disease. Undoubtedly, improving the knowledge and skills of health care workers trusted by their communities can be a valuable resource to promote successful vaccination campaigns and improve the overall acceptance of COVID-19 vaccines. The health care workers must engage in the education and motivation of the patients, which makes the latter feel safe, respected, and provided with an opportunity to make informed health-related decisions more accurately. Future studies systematically reviewing the minor and serious adverse reactions to COVID-19 vaccines would improve vaccine acceptance, by the expansion of traditions views that weight the risk and benefits associated with COVID-19 vaccines.

DISCLAIMER

The products used for this research are commonly and predominantly used in our research area and country. There is no conflict of interest between the authors and producers of the products because we do not intend to use these products as an avenue for litigation but the advancement of knowledge. Also, the research was not funded by the producing company; instead, it was financed by the personal efforts of the authors.

CONSENT AND ETHICAL APPROVAL

As per international standard or university standard written ethical approval has been collected and preserved by the author(s). The statements, texts and photographic materials used in this report have been consented by the patient to be made available for in variety of formats and platforms by the reporting author.

COMPETING INTERESTS

Authors have declared that no competing interests exist.

REFERENCES

1. Schmieder S, Harper C, Schmieder G. Granuloma Annulare [Internet]. Ncbi.nlm.nih.gov; 2021. [Cited 12 November 2021].

- Available: https://www.ncbi.nlm.nih.gov/books/NBK459377/#_NBK459377_pubdet_
2. Thornsberry LA, English JC. Etiology, diagnosis, and therapeutic management of granuloma annulare: An update. *Am J Clin Dermatol.* 2013;14(4):279-290. DOI: 10.1007/s40257-013-0029-5
3. Ritchie H, Mathieu E, Rodés-Guirao L, Appel C, Giattino C, Ortiz-Ospina E et al. Coronavirus Pandemic (COVID-19) [Internet]. Our World in Data; 2021 [cited 12 November 2021]. Available: https://ourworldindata.org/covid-vaccinations?country=OWID_WRL
4. Cheng Y, Tsai W, Chuang F, Chern E, Lee C, Sung C et al. A retrospective analysis of 44 patients with granuloma annulare during an 11-year period from a tertiary medical center in south Taiwan. *Dermatologica Sinica.* 2016;34(3):121-125.
5. Rosenbach MA, Wanat KA, Reisenauer A, White KP, Korcheva V, White CR. Non-infectious granulomas. In: Bologna JL, Schaffer JV, Cerroni L, eds. *Dermatology.* 4th ed. Elsevier; 2018:1644-1663
6. Akinosoglou K, Tzivaki I, Marangos M. Covid-19 vaccine and autoimmunity: Awakening the sleeping dragon. *Clinical Immunology.* 2021;226:108721.
7. Who.int. 2021 [cited 12 November 2021]. Available: https://www.who.int/docs/default-source/coronaviruse/risk-comms-updates/update58-the-role-of-health-workers-in-the-uptake-of-covid-19-vaccines.pdf?sfvrsn=11c90bec_6
8. García-Gil M, Álvarez-Salafranca M, Martínez García A, Ara-Martín M. Generalized granuloma annulare after pneumococcal vaccination. *Anais Brasileiros de Dermatologia.* 2021;96(1): 59-63.
9. Lepe K, Riley C, Salazar F. Necrobiosis Lipoidica [Internet]. Ncbi.nlm.nih.gov. 2021 [cited 12 November 2021]. Available: <https://www.ncbi.nlm.nih.gov/books/NBK459318/>
10. Hsu S, Le EH, Khoshevis MR. Differential diagnosis of annular lesions. *Am Fam Physician.* 2001;64(2):289-296.
11. García-Gil M, Álvarez-Salafranca M, MartonesGarciaa A, Ara-Martín M. Generalized granuloma annulare after

- pneumococcal vaccination. Anais Brasileiros de Dermatologia. 2021;96(1): 59-63.
12. Kaur S, Gupta V. COVID-19 Vaccine: A comprehensive status report. Virus Research. 2020;288:198114.
13. Kaur S, Gupta V. COVID-19 Vaccine: A comprehensive status report. Virus Research. 2020; 288:198114.
14. Available:https://www.seruminstitute.com/product_covishield.php

© 2021 Shri and Thomas; This is an Open Access article distributed under the terms of the Creative Commons Attribution License (<http://creativecommons.org/licenses/by/4.0>), which permits unrestricted use, distribution, and reproduction in any medium, provided the original work is properly cited.

Peer-review history:
The peer review history for this paper can be accessed here:
<https://www.sdiarticle5.com/review-history/76523>